Cite this article:
Meyer GB, Bernhardt O, Constantinescu MV, Fundamentals of Occlusion and Masticatory Function. Stoma Edu J. 2014; 116-122

FUNDAMENTALS OF OCCLUSION AND MASTICATORY FUNCTION

Georg B. Meyer[1a*], Olaf Bernhardt[2b], Marian-Vladimir Constantinescu[3c]

1. Zentrum für Zahn- Mund-, und Kieferheilkunde, Universitätsmedizin Greifswald, Greifswald, Germany
2. Poliklinik für Zahnerhaltung, Parodontologie und Endodontologie, Universitätsmedizin Greifswald, Greifswald, Germany
3. Department of Prosthetic Dentistry, "Carol Davila" University of Medicine and Pharmacy Bucharest, Romania

a. DMD, PhD, Dr hc, Professor and Chairman
b. DMD, PhD, Professor
c. DDS, PhD, Professor

Abstract

Aim: Craniomandibular dysfunction is an expression of the dysfunctional masticatory system. It may have diverse risk factors, like occlusal interferences, including traumatic amalgam fillings and other fillings.
The article aims to present three cases of craniomandibular dysfunction generated by occlusal interferences.
Methodology: Three patients with different forms of craniomandibular dysfunction were referred to dentist for evaluation and treatment.
Results: Occlusal interferences were identified as the main risk factor for uncoordinated hyperactive muscles and for craniomandibular dysfunction diagnosed in three cases presented. After occlusal correction, muscular dysfunction disappeared.
Conclusions: In case of reasonable suspicion of craniomandibular dysfunction, an estimate for the detailed clinical and possibly instrumental diagnostics and optionally (grinding teeth guare/bite splint) pre-treatment must be done. Only after pre-treatment definitive treatments can be planned and carried out.

Keywords: craniomandibular dysfunction, occlusal interferences, masticatory function

Physiological aspects of the masticatory function

In the undisturbed masticatory system, the teeth are in neutral occlusion with each other (Fig. 1). That is why, the most important is the natural contact of the cusps and fissures of the antagonist teeth, in order that all the eccentric movements won't bring any disturbance (Fig. 2). The temporo-mandibular joints are in statics but also in dynamics of the same growth-related geometry, in order to have the temporo-mandibular joints as "distal pairs of occlusion".

When loaded during chewing, the involved teeth will be depending on the consistency of the alimentary bolus to be crushed, and they will be deflected spatially within their physiological mobility (Fig. 3). This requires the elastic and damping properties of the periodontal apparatus. In this area there are nerve endings, on which on which are generally mechano-receptors (Fig. 4).

The capture caused by the respective bolus changes the position of the teeth by approximately10 to 20 microns, which corresponds approximately to the thickness of a human hair. This information is passed via afferent nerve pathways (sensors) in the central nervous system (Fig. 5). Here, a coordination of afferents and a conversion via synaptic structures in efferent signals is induced, which are passed to the motor units of the muscles, so that finally in the right place (localization of the bolus) with adequate power use (consistency of the bolus) chewing can occur. Overall, these are physiological control loop mechanisms, programmed in the growth phase and matched, that is why, for example, grinding and clenching in children may be physiologically. Ultimately, in the adult undisturbed masticatory all the geometric occlusal forces and temporo-mandibular joint functions with neuromuscular function sequences are working together in harmony. Temporary psycho-emotional stress situations with a clenching of the teeth does not lead to any direct damage to normal mastication, but are apparently even planned by nature for reducing the stress.

Received: 17 October 2013
Accepted: 24 November 2013

*** Corresponding author:**
Professor Georg B. Meyer, DMD, PhD, Dr hc, Chairman
Zentrum für Zahn-, Mund- und Kieferheilkunde, Ernst-Moritz-Arndt Universität, Rotgerberstraße 8, D-17475 Greifswald, Germany.
Tel: +493834867130, Fax: +493834867171.
e-mail: gemeyer@uni-greifswald.de

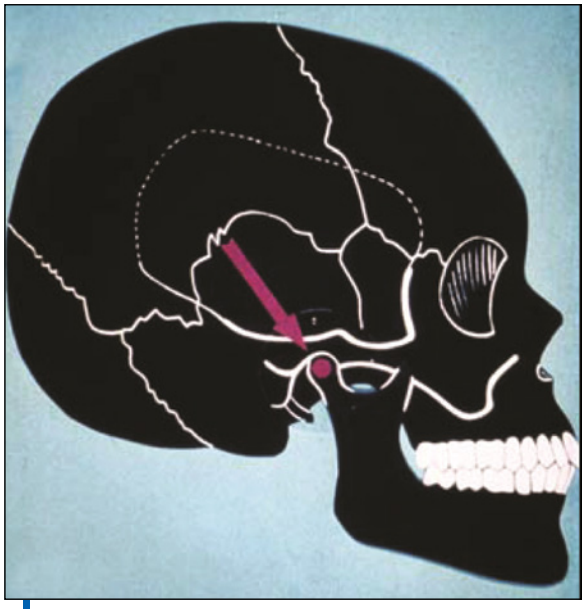

Figure 1. The condyles of the jaw joints can be found in its zero position / centric

Figure 3. The geometry of cusps and fissures antagonistic teeth allows undisturbed movement sequences in chewing

Pathological aspects of the masticatory function

Typical primary damages in the masticatory system, which can be caused by occlusion and / or hyperactive muscles, are wear facets, tooth and filling fractures, pseudopultitis, periodontal overloading, that can cause increased tooth mobility and progressivebone loss, hypersensitive tooth necks, and wedge-shaped defects (Fig. 7). Masticatory Disorders are primarily caused by occlusal discrepancies, when this area of the periodontal ligament (10-20 microns) significantly exceededs or undercuts (Utz, 1986). The Japanese Kobayashi (1988) created the basis of experimental investigations shown in sleep laboratories, that premature contacts to occlusal restorations grew in the order of 100 micrometers, and lead to : 10 times

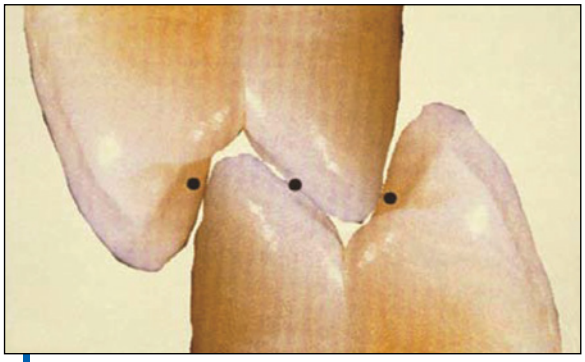

Figure 2. In undisturbed biomechanics upper and lower teeth fit clearly into one another

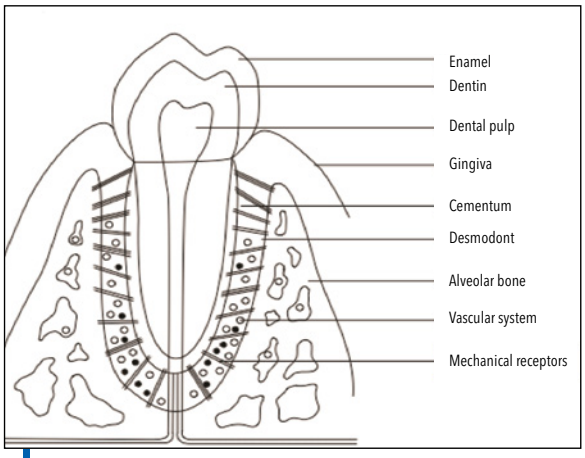

Figure 4. Natural teeth have a physiological mobility due to their elastic suspension. Mechanoreceptors in the periodontium detect changes in position with an accuracy of 10-20 microns

increase of the periodontal tactility, increased muscle activity, bruxism, insomnia, increased adrenaline, sleep apnea, TMJ disorders & reduced performance. Kordaß et al. (2009) were able to prove functional MRI that Masticatory Disorders led to an increased metabolism in areas of the brain. Lotzmann (1994) found in a diagnostic-therapeutic-oriented dental follow-up of patients that were previously diagnosed with "neuralgia" by neurologists, that in up to 50 percent of cases, occlusion disorders were the main cause of the neuralgieformen disorders. Graber (1995) demonstrated that the psycho-emotional stressors can be the decisive gains of dysfunctional-related diseases of the stomatognathic system. In fact, clinical experience confirms, that existing occlusal trauma comes after the occurrence of stress to symptoms of illness. In other words, clenching and grinding can especially lead to head and facial pain, if the occlusion is not in harmony, because the muscular hyperactivity is thusintensified. Bernhardt et al. (2005) found significant correlations between a high incidence of headache in approximately 4200 subjects in an epidemiological study (SHIP), that suffered from tension in the masticatory muscles. In conclusion, the authors found that a clarification

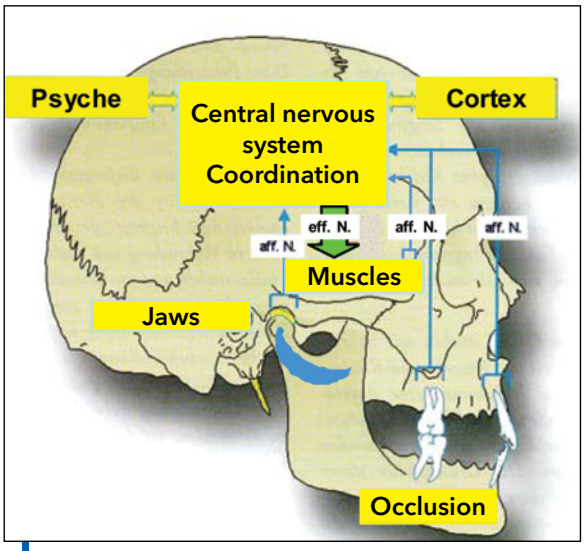

Figure 5. Information from the region of the teeth, e.g., consistency and position of a bolus, go through afferent nerves (aff. N.) to the central nervous system. After appropriate coordination (eff. N.) the muscles are controlled from there via efferent nerves, so that the masticatory function can proceed undisturbed

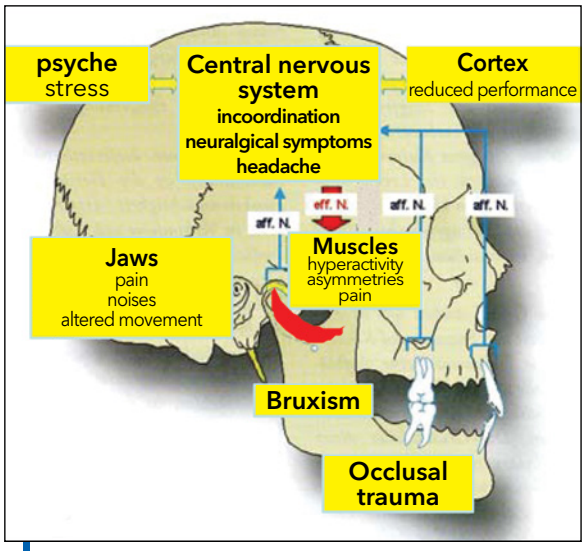

Figure 6. As the occlusal interference may give contradictory signals from the area of the teeth to the central nervous system that can be no longer well-coordinated there. There is a malfunction in the chewing system that may develop in a very different way in different individuals

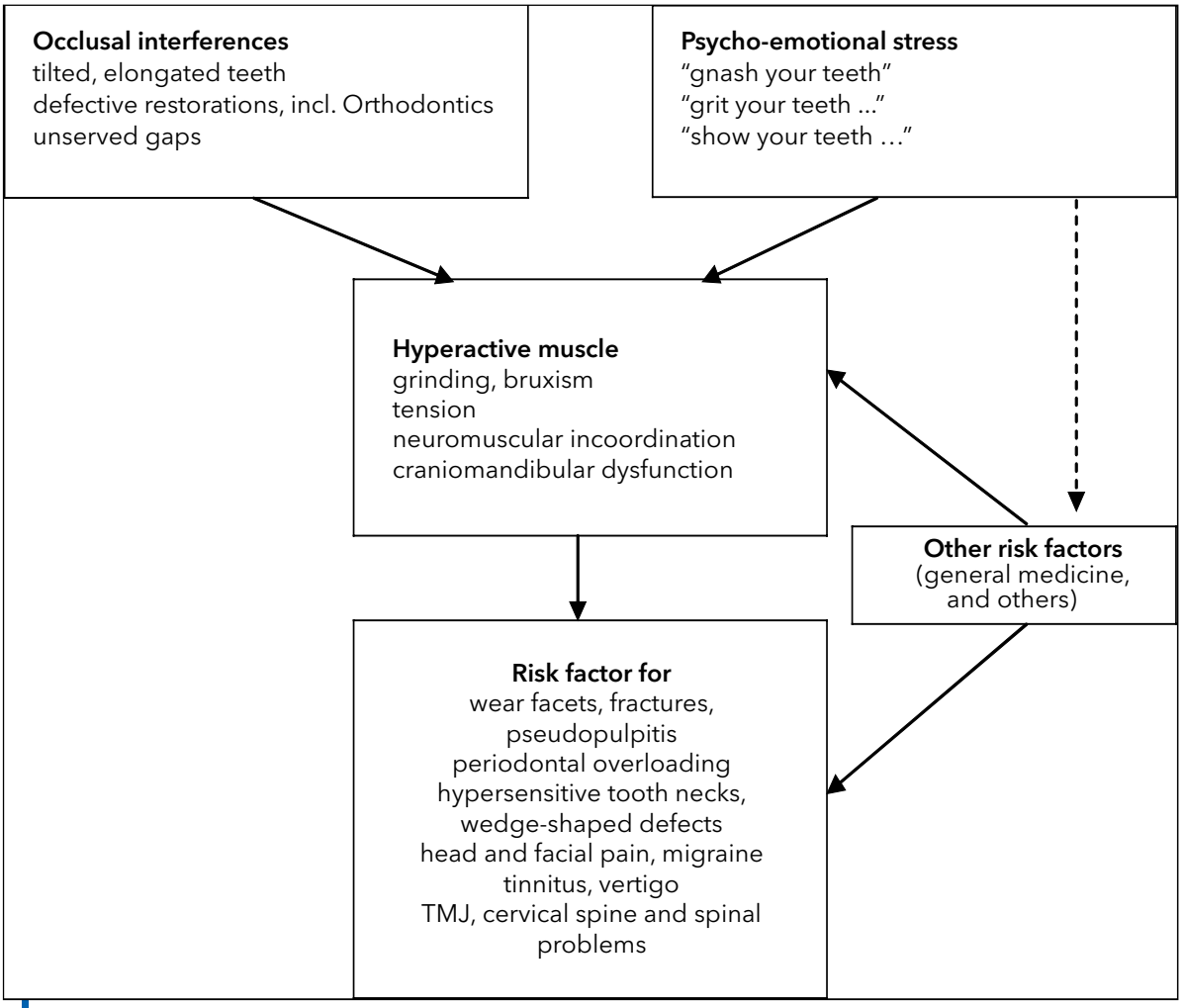

Figure 7. Craniomandibular dysfunctions (CMD) have multiple risk factors, which include occlusal interferences. CMD in turn is a risk factor for symptoms that are not often associated with dentistry

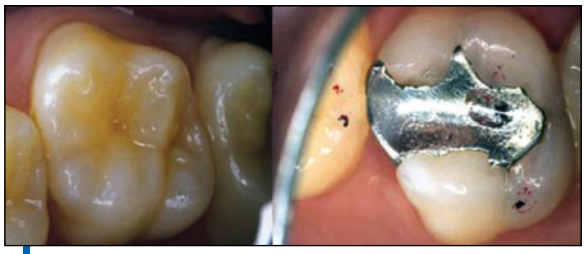

Figure 8. Left: an untreated, natural upper molar. Right: an amalgam filling with distinctly pronounced abrasionabraded facet, which may be a trigger of CMD

Figure 10. As a possible risk factor, a poorly designed amalgam filling was found at a lower molar

Figure 9. This patient had tremors in the area of masseter muscle, which he willingly could not influence

Figure 11. According correction of amalgam filling gave the patient a spontaneous "better feeling" to. The tremor did not occur since then

Figure 12. A patient with muscle-related restricted mouth opening shows as single risk factor this amalgam filling on an upper molar

of frequent head pain within the interdisciplinary diagnostic must also include an investigation of the dental causes.

The same applies to the tinnitus, as very recent studies show. In summary it can be stated that craniomandibular dysfunction (CMD) can be used as an expression of the dysfunctional masticatory system. It may have diverse risk factors which may, in part, have to be classified to be far outside the scope of our art (Fig. 7). From the perspective of dentistry, when diagnostics and therapy of CMD-based diseases are concerned you will have to think primarily of occlusal interferences, including traumatic amalgam fillings and other fillings (Fig. 8).

Clinical patient cases

First case

This patient had for some time twitching activities periodically occurring on both sides in the masseter muscles, that he deliberately could not control.

Figure 13. Immediately after correction of the amalgam filling, there occurred a relaxation of the muscles. Within a few days an unrestricted oral opening was possible

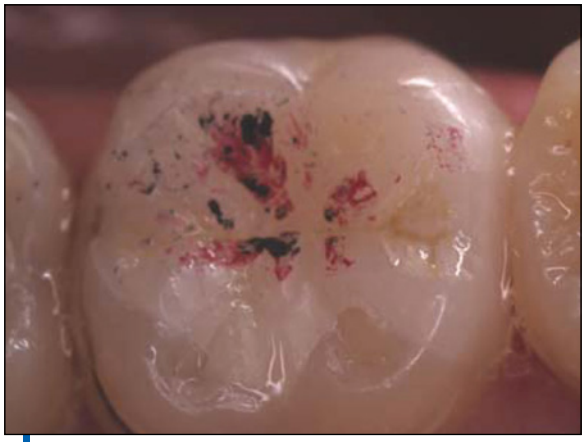

Figure 14. Massive centric and eccentric series contacts on a ceramic restoration

Figure 15. Correction of these ceramic restorations gave the patient a balanced-fit-feeling

Findings	Yes	No
1. Mouth opening asymmetrical	❑	❑
2. Mouth opening restricted	❑	❑
3. Traumatic excentric movements	❑	❑
4. TMJ noises, pain	❑	❑
5. Muscle palpation (M. masseter/temporalis) asymmetrically positive finding	❑	❑

Evaluation

max. 1 pos. finding: health probable

3 or more pos. findings: disease probable

Supplemental finding	Yes	No
6. Physiological centric position unequal max. intercupation "Cotton-Roll-Test" (early contacts, occlusal gliding, enamel chipping, grinding facettes, wedge-shaped defects, tooth mobility, tongue impressions etc.)	❑	❑

Evaluation

With pos. finding: disease probable

mod.n Ahlers / Jakstat

Figure 16. The Ahlers and Jakstat clinical summary report for CMD risk identification was extended by a test of physiological centric position

General medical and neurological examinations were unsuccessful and ultimately relaxation therapies were recommended. A mere-chance-conversation lead to an inspection that showed a single occlusal risk factor: distinct wear facets on an amalgam filling at a lower molar. At the same consultation this filling was corrected by grinding using magnifying spectacles and using 10-micron thin occlusal foil. These fissures were so engrossed and moved that the maximum intercuspation and all eccentric movements were possible (Fig. 9, 10, 11). Spontaneously releasing the patient, he would now have an even bite together, and he felt much more relaxed. The muscle irritations were now no longer on.

Second Case

This patient came to our clinic because of restricted mouth opening of about 25 mm interincisal distance (IID). As a risk factor, an amalgam filling was found on an upper molar, which had a massive abrasionfacet. The amalgam filling was remodeled according to the natural model. The patient was spontaneously changed to a pleasant- fit-feeling.

Because of photo documentation the session took a total of about 45 minutes. In the end, the patient was able to achieve an opening of 38 mm IID, which was apparently due to a spontaneous relaxation of the muscles. Within a few days they then reached an unrestricted mouth opening of about 40 millimeters IID (Fig. 12, 13).

Third case

This patient was referred by a neurologist due to severe tension headaches of unknown origin. It had to be clarified whether dental risk factors may be identified that could causally contribute to this disease. In clinical occlusion diagnostics centric and eccentric premature contacts were found on a ceramic restoration in a mandibular molar. Immediately after correction the patient showed a balanced-fit-feeling of all the teeth of the maxilla

and mandible (Fig. 14, 15). After a few days, the headache was gone.

Summary and outlook

From the perspective of dentistry, occlusal interferences are the main risk factor for uncoordinated hyperactive muscles and thus also for CMD. In severe malocclusion, which cannot be immediately eliminated for various reasons, for example infraocclusions, the initial occlusion is performed on the basis of a corresponding point registration with occlusion aids. Only after successful treatment of CMD, which is accompanied usually by achieving a physiological centric, definitive occlusal and / or restorations and orthodontics can be planned and carried out.

An initial, relatively reliable, short clinical function and occlusion diagnosis to exclude CMD is the condensed clinical report (Fig. 16).

Bibliography

1. Ahlers MO, Jakstat HA. Klinische Funktionsanalyse – Interdisziplinäres Vorgehen mit optimierten Befundbögen. 3. Aufl. Hamburg: dentaConcept, 2007.
2. Ash MM. Schienentherapie. München: Urban & Fischer, 2006.
3. Bernhardt O, Gesch D, Schwahn C, Mack F, Meyer G, John U, Kocher T. Risk factors for headache, including TMD signs and symptoms and their impact on quality of life. Results of the Study of Health in Pomerania (SHIP). Quintessence Int 2005;36(1):55-64.
4. Bernhardt O, Gesch D, Schwahn C, Bitter K, Mundt T, Mack F, Kocher T, Meyer G, Hensel E, John U. Signs of temporomandibular disorders in tinnitus patients and in a population-based group of colunteers: results of the Study of Health in Pomerania. J Oral Rehabil 2004;31(4):311-319.
5. Ekberg E, Vallon D, Nilner M. The efficacy of appliance therapy in patients with temporomandibular disorders of mainly myogenous origin. A randomized, controlled, short-term trial. J Orofac Pain 2003;17(2):133-139.
6. Freesmeyer WB. Zahnärztliche Funktionstherapie. München: Hanser, 1993.
7. Fu AS, Mehta NR, Forgione AG, Al-Badawi EA, Zawawi KH. Maxillomandibular relationship in TMD patients before and after short-term flat plane bite plate therapy. Cranio 2003; 21(3):172-179.
8. Göbel H. Erfolgreich gegen Kopfschmerzen und Migräne. 3. Aufl. Berlin: Springer, 2002.
9.Graber G. Der Einfluss von Psyche und Stress bei dysfunktionbedingten Erkrankungen des stomatognathen Systems. In: Koeck B (Hrsg). Funktionsstörungen des Kauorgans. Praxis der Zahnheilkunde Bd 8. München: Urban & Schwarzenberg, 1995.
10. Hupfauf L, Weitkamp J. Ergebnisse der Behandlung von funktions- bedingten Erkrankungen des Kausystems mit Aufbissbehelfen. Dtsch Zahnärztl Z 1969; 24(5):347-352.
11. Kobayashi Y, Hansson TL. Auswirkungen der Okklusion auf den menschlichen Körper. Phillip J Restaur Zahnmed. 1988;5(5):255-263.
12. Kordass B, Lucas C, Hützen D, Zimmermann C, Gedrange T, Langner S, Domin M, Hosten N. Functional magnetic resonance imaging of brain activity during chewing and occlusion by natural teeth and occlusal splints. Ann Anat 2007;189(4):371-376.
13. Kovarik R.E. Restoration of posterior teeth in clinical practice: evidence base for choosing amalgam versus composite. Dent Clin North Am. 2009;53(1)71-76.
Kreyer G. Das Orofazialsystem als Schnittstelle zwischen Psyche und Soma. Zahnärztl Mitt 2005;95:1366-1371.
14. Küppers A, Holtfreter B, Kordaß B, Bernhardt O. Okklusaler und inzisaler Verschleiß von Zahnhartgewebe und dentalen Restaurationsmaterialien. Ergebnisse einer populationsbasierten Probandengruppe aus dem assoziierten Projektbereich der regionalen Basisstudie Vorpommern – Studie of Health in Pomerania (SHIP). 42. Jahrestagung DGFDT. 04./05.12.2009 Bad Homburg.
15. Lotzmann U. The effect of divergent positions of maximum intercuspation on head posture. J Gnathol 1991;10:63-68.
16. Lotzmann U. Okklusionsschienen und andere Aufbissbehelfe. Müchen: Neuer Merkur, 1992.
17. Lotzmann U, Vadokas V, Steinberg JM, Kobes L. Dental aspect of the differential diagnosis of trigeminal neuralgia. J Gnathol 1994;13:15-22.
18. Maug C, Hoffmann S, Gerlach AL, Colak-Ekici R, Evers S, Rist F, Wolowski A. Okklusale Störungen als Prädiktor der Masseteraktivierung durch eine psychologische Stressbelastung - Ein interdisziplinäres Forschungsprojekt Dtsch Zanärztl Z 2007;62: D46.
19. Melchart D, Vogt S, Köhler W, Streng A, Weidenhammer W, Kremers L, Hickel R, Felgenhauer N, Zilker T, Wühr E, Halbach S. Treatment of health complaints attributed to amalgam. J Dent Res. 2008;87(4):349-353.
20. Meyer G. Die physiologische Zentrik im Rahmen der instrumentellen Okklusionsdiagnostik. In: Akademie Praxis und Wissenschaft in der DGZMK (Hrsg). Funktionslehre. Schriftenreihe APW. München: Hanser, 1993.
21. Meyer G, Bernhardt O, Asselmeyer T. Schienentherapie heute. Quintessenz 2007;58(5):489-500.
22. Meyer G, Bernhardt O, Küppers A. Der Kopfschmerz – ein interdisziplinäres Problem. Aspekte der zahnärztlichen Funktionsdiagnostik und –therapie. Quintessenz 2007;58(11):1211-1218.
23. Motsch A. Die Amalgamfüllung – Heute!. Unterrichtsschrift, Göttingen 1992. 8. überarbeitete und erweiterte Auflage, Greifswald 2009.
24. Schmalz G, Geurtsen W, Arenholt-Bindslev D. Die Biokompatibilität von Komposit-Kunststofffüllungen. Dtsch Zahnärztl Z 2005; 60:563-576.
25. Schulte W. Die exzentrische Okklusion. Berlin: Quintessenz, 1983.
26. Slavicek R. Das Kauorgan: Funktionen und Dysfunktionen. Klosterneuburg: Gamma-Verlag, 2000.
27. Utz K-H. Untersuchungen über die taktile Feinsensibilität natürlicher Zähne mit Hilfe von Aluminium-Oxid-Teilchen. Dtsch Zahnärztl Z 1986;41:313-316.
28. Wright EF. Otologic symptom improvement through TMD therapy. Quintessence Int 2007;38(9):564-571.