

Cite this article:

Perlea P, Nistor CC.
Healing of Periapical
Periodontitis – Cone Beam
Computed Tomography
Visualization – Case
Report.
Stoma Edu J. 2014;1(2):
98-101.

HEALING OF PERIAPICAL PERIODONTITIS - CONE BEAM COMPUTED TOMOGRAPHY VISUALIZATION - CASE REPORT

**Paula Perlea^{a*},
Coralia Cristina Nistor^b**

Department of Endodontology, Faculty of Dental
Medicine, "Carol Davila" University of Medicine and
Pharmacy, Bucharest, Romania
a. MD, PhD, Specialist in endodontics, Senior Lecturer
b. MD, Specialist in endodontics, Senior Lecturer

Abstract

Aim: The clinical case highlights the outcome of a large periapical periodontitis using radiograph compared with Cone Beam Computed Tomography (CBCT).

Summary: Periapical periodontitis is one of the most frequent reasons for endodontic treatments. The outcome of the endodontic procedures can be assessed either by radiographs or Cone Beam Computed Tomography (CBCT). The periapical radiolucency can increase, decrease or resolve over a period of time. CBCT, as compared to periapical (PA) radiographs shows higher accuracy in detecting the real extend of periapical lesions, facilitating the visualization of the outcome of the treatment.

Key learning points:

Even larger periapical periodontitis can be treated in a single visit.

No medication or surgical procedures are needed for a positive outcome of endodontic treatment of periapical lesions.

Radiographs provide limited information about the healing of periapical pathosis.

Radiographs do not detect smaller periapical radiolucency.

CBCT shows more accurate detection of apical periodontitis.

Keyword: periapical periodontitis, radiograph, CBCT, endodontics, outcome

Introduction

The presence of bacteria in the root canal system and the marginal leakage of the tooth restoration with penetrating caries lead to persistent periapical periodontitis. Medication beyond the apex has no effect, because chronical lesions are considered sterile (1). Surgical elimination of the lesion might be an alternative. The first choice in periapical periodontitis should be the orthograde treatment. The purpose of this procedure is to eliminate the infected content of the endodontic system and to seal it with a proper root canal filling. Correct treatment leads to a reduction or complete healing of the periapical lesion. The outcome of an endodontic treatment can be visualized using periapical (PA) radiographs or Cone Beam Computed Tomography (CBCT).

Our clinical case highlights the healing of periapical periodontitis after a single-visit treatment revealed on a CBCT compared with PA radiograph.

Clinical Case

A 51 year old patient was referred to our endodontic department for endodontic treatment of tooth 47. The clinical examination revealed a large caries penetrating into the pulp chamber. The tooth was slightly positive to percussion and the vitality test showed negative response. No swelling or draining sinus could be detected. There was no periodontal probing more than 3 mm. The initial periapical radiograph showed a radiolucency due to infection noted around both the mesial and distal roots of tooth 47 (Fig. 1). Rubber dam was placed and the alterate dentine was removed. The coronal walls were reconstructed using glass ionomer cement.

Received: 19 November 2014
Accepted: 28 December 2014

*** Corresponding author:**

Senior Lecturer Paula Perlea, MD, PhD,
57 Levantica Str, District 3,
RO-031402 Bucharest, Romania.
Tel: +40744 377 011, Fax: +40213468888,
e-mail: paula.perlea@gmail.com

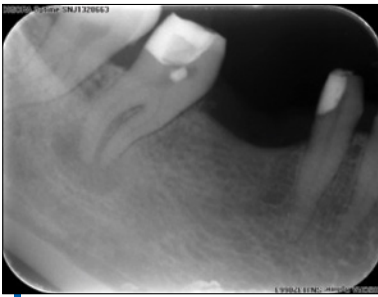


Figure 1. Preoperative radiograph of 47

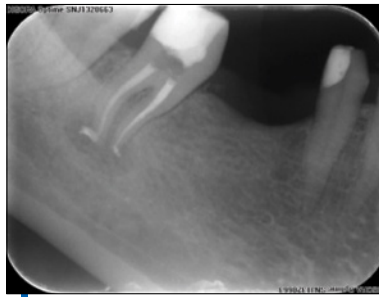


Figure 2. Postoperative radiograph of 47

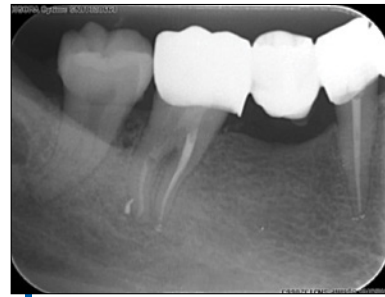

Figure 3. One year follow-up

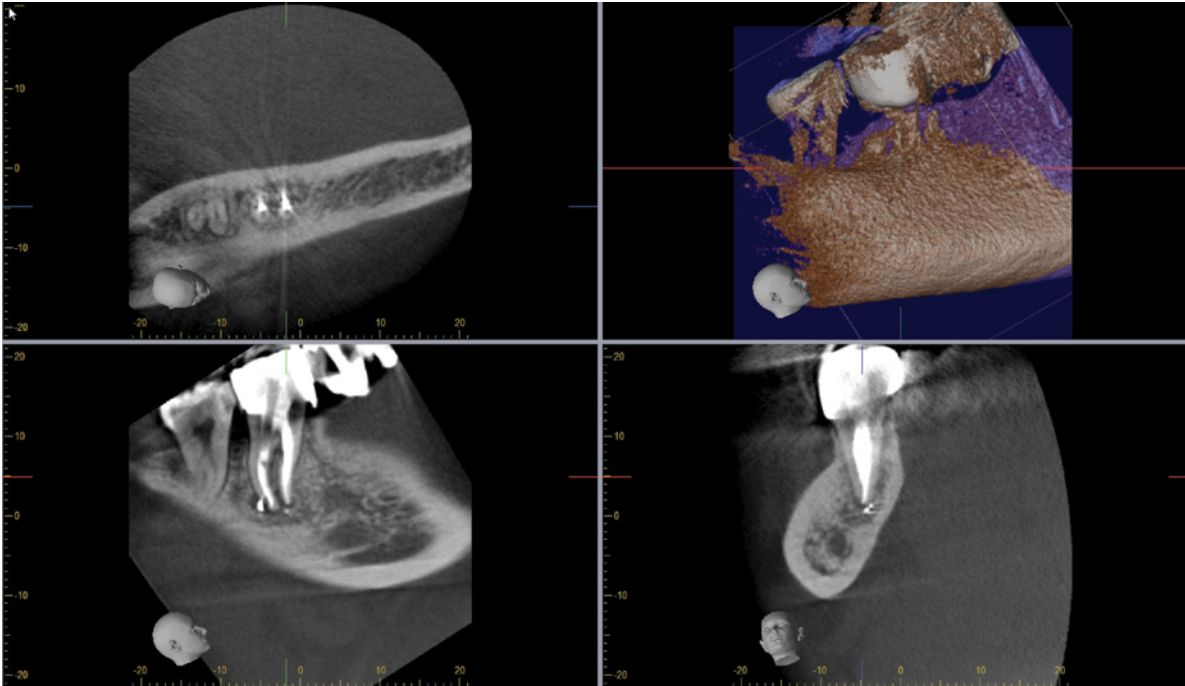


Figure 4. CBCT showing the periapical radiolucency in the sagittal (lower left window) and the coronal view (lower right window)

The root canal treatment was performed in a single visit. Full working lengths were achieved for all three canals. After negotiating the canals with manual instruments, ProTaper Universal rotary instruments (Dentsply, Maillefer, Switzerland) was used for shaping and cleaning. Preheated 5,25% NaOCl and 17% EDTA were used as irrigants. After drying the canal, the root canal filling was performed using warm vertical condensation of gutta-percha (Fig. 2). A post was inserted and the tooth was crowned. The one year follow-up radiograph shows complete healing of the periapical lesion (Fig. 3). On the other hand, on the CBCT, especially in the coronal plan, we can visualize a clear radiolucency, CBCT-PAI 2 (Fig. 4).

Conclusions

CBCT is a great asset in daily endodontics, especially in the diagnosis of periapical endodontic pathosis and in the assessment of the success or failure after endodontic treatment (progression of healing of the periapical periodontitis).

CBCT is a relatively new technology which should be introduced in daily dentistry. In 2010, Dr Martin Level, member of The American Board of Endodontics was considering that 42% of the patients had to be scanned (2). The radiological beam is cone shaped and needs one single rotation for acquiring the 3D images. The visualization is axial, transaxial, coronal and sagittal.

Conventional radiography is essential for an accurate endodontic diagnosis (3). However, the classical radiography is the two-dimensional expression (mesial-distal) of a three-dimensional reality, ignoring the vestibulo-lingual plane/direction (4). The information thus obtained is relative because of the incidence of the radiography.

Periapical pathosis cannot be correctly viewed on a retroalveolar, isometric and orthoradial radiograph, considering the overlapping of the anatomical structures, the anatomic noise and the geometric distortion. The conventional radiograph provides us with limited information regarding the localization and the real extent

of periapical, lateral or interradicular chronic periodontitis (5). The CBCT can provide crucial information even for the identification of small periapical lesions, which cannot be identified on periapical conventional radiograph. Friedman demonstrated that early endodontic treatment increases the success rate of endodontic treatment, when periapical pathosis was detected on CBCT prior to conventional radiograph, which could not reveal the radiolucency yet (6, 7). Huuononen proved the accuracy of CBCT in the diagnosis of chronic periapical periodontitis in the case of patients with diffuse pain and inconclusive clinical tests when radiographs showed no pathological modifications (8).

Unlike the conventional X ray which gives a two dimensional view, the CT scanner can reveal

all the three dimensions, providing accurate informations about the size of the radiolucency. A decrease in size of a periapical radiolucency, even if the lesion is not completely remineralized, is a sign of healing (9).

The sensitivity of periapical radiographs is lower compared with the CBCT (10, 11).

The radiographic outcome determined with PA radiographs could be untrue (12).

Just CBCT makes accurate diagnosis of periapical lesions possible, when a lower dose conventional radiography cannot provide a precise diagnosis. Limited volume CBCT is preferred. The small size of the field of view (FOV), the beam collimation, the shortest time and the smallest voxel decreases the radiation exposure when using CBCT in endodontics.

Bibliography

1. Castellucci A. Endodontics volume I, Il Tridente Firenze. 2004; 160-207
2. <http://www.studiodentisticovenuti.it/wp-content/uploads/2012/06/cone-beam-articolo.pdf> 3.
3. Patel S. New dimensions in endodontic imaging: Part 2. Cone beam computed tomography, Int Endod J 2009;42(6):463-475.
4. Velvart P, Hecker H, Tillinger G. Detection of the apical lesion and the mandibular canal in conventional radiography and the computed tomography, Oral Surg Oral Med Oral Pathol Oral Radiol Endod 2001;92(6):682-688.
5. Garcia de Paula-Silva FW, Hassan B, Bezerra da Silva LA, Leonardo MR, Wu MK. Outcome of root canal treatment in dogs determined by periapical radiography and cone-beam computed tomography scans. J Endod. 2009;35(5):723-726.
6. Lofthag-Hansen S, Huuononen S, Gröndahl K, Gröndahl HG. Limited cone-beam CT and intraoral radiography for the diagnosis of periapical pathology. Oral Surg Oral Med Oral Pathol Oral Radiol Endod. 2007;103(1):114-119.
7. Friedman S. Prognosis of initial endodontic therapy. Endod Top 2002; 2:59-98
8. Huuononen S, Kvist T, Gröndahl K, Molander A. Diagnostic value of computed tomography in re-treatment of root fillings in maxillary teeth. Int Endod J 2006;39(10):827-833.
9. European Society of Endodontology. Quality guidelines for endodontic treatment: consensus report of the European Society of Endodontology. Int Endod J 2006;39(12):921-930.
10. Low KM, Dula K, Bürgin W, von Arx T. Comparison of periapical radiography and limited cone-beam tomography in posterior maxillary teeth referred for apical surgery. J Endod. 2008;34(5):557-562.
11. Tsai P, Torabinejad M, Rice D, Azevedo B. Accuracy of cone-beam computed tomography and periapical radiography in detecting small periapical lesions. J Endod. 2012; 38(7):965-970.
12. Metska ME, Liem VM, Parsa A, Koolstra JH, Wesselink PR, Ozok AR. Cone-beam computed tomographic scans in comparison with periapical radiographs for root canal length measurement: an in situ study. J Endod. 2014;40(8):1206-1209.