

Cite this article:

Javed F, Romanos GE. A comprehensive review of various laser-based systems used in early detection of dental caries. *Stoma Edu J.* 2015;2(2):108-113.

A COMPREHENSIVE REVIEW OF VARIOUS LASER-BASED SYSTEMS USED IN EARLY DETECTION OF DENTAL CARIES

[https://doi.org/10.25241/stomaeduj.2015.2\(2\).art.2](https://doi.org/10.25241/stomaeduj.2015.2(2).art.2)

Fawad Javed^{1a}
Georgios E. Romanos^{2b*}

Abstract

¹ Division of General Dentistry, Eastman Institute for Oral Health, University of Rochester, NY 14620, USA.

² School of Dental Medicine, Stony Brook University, Stony Brook, NY, USA.

^aBDS, PhD, Research Associate
^bDDS, DMD, PhD, Professor

Introduction: The aim was to comprehensively review the various laser-based systems used in early detection of dental caries.

Methodology: PubMed/Medline and Google-scholar databases were searched from 1995 up to June 2015 using various combinations of the following keywords: "dental early caries", "diagnosis", "laser" and "light fluorescence" (LF). Literature reviews, letters to the Editor, and commentaries were excluded. Articles published only in English were included. The pattern of the present study was customized to primarily summarize the pertinent information.

Results: Laser fluorescence at 655 nm (DIAGNOdent) is a promising tool for early detection of occlusal caries. Other systems based on the LF concept include VistaProof (VP) and DIAGNOdent Pen; however, no statistically significant difference in the caries detection efficacy has been reported between VP, DIAGNOdent Pen and DIAGNOdent devices. Although light emitting diode systems have also been tested for detecting caries, their diagnosing efficacy remains unclear due to a lack of studies.

Conclusion: Lasers-based caries detection systems are useful tools in the early detection of caries in contrast to traditional visual and radiographic examination techniques; however, further studies are needed to assess the caries diagnostic efficacy of the various commercially available laser-based caries diagnostic systems.

Keywords: dental early caries, diagnosis, laser and light fluorescence, light emitting diode

Introduction

Dental caries (or caries) represent a chronic disease of the mineralized tissues of teeth, namely (enamel, dentin and cementum) caused by the action of cariogenic bacteria on fermentable carbohydrates leading to the demineralization of these mineral portions and (if left untreated) disintegration of their organic matrix.¹ Traditionally, caries are diagnosed by visual clinical examination (for example, visualizing the size and depth of the lesion using mechanical probes) and radiographs (such as bite-wing images)²; however, these techniques are able to detect carious lesions only at an advanced stage.³ Yet, specificity of visual examination for the diagnosis of caries has been reported to be high; the methodology exhibits low sensitivity and reproducibility.⁴ Likewise, although digital radiography

(such as digital intra-oral and extra-oral radiographs and three-dimensional computed tomography) is a modernization in imaging technology⁵⁻⁷; the potential risk of radiation hazards associated with these techniques, remains inevitable.

Novel techniques have been assessed as diagnostic tools to identify and quantify initial demineralization. Laser fluorescence (LF) (in the visible region, blue or red) has been reported to be a valuable tool for early diagnosis of caries.^{8,9} Caries detecting devices based on the LF mechanism include DIAGNOdent 2095 and DIAGNOdent 2190 (LF and LFpen, KaVo, Biberach, Germany). Results by Takamori et al.¹⁰ showed that LF is useful in the early diagnosis of occlusal caries. LF has also shown promising results in the detection of caries in deciduous teeth.^{11,12} Likewise, other LF-based devices comprising of a light-emitting-diode (LED)

Received: July, 1st 2015
Accepted: July, 14 2015

* Corresponding author:

Professor Georgios E. Romanos
School of Dental Medicine
Stony Brook University, Stony Brook, NY, USA
Tel: +1 (631) 632-8755
Fax: +1 (631) 632-8670

Email: Georgios.Romanos@stonybrookmedicine.edu




Figure 1a-b. (a) Classic DIAGNOdent system (b) DIAGNOdent (pen)
(Source of image: <http://cariology.wikifoundry.com/page/Laser+Fluorescence+and+Quantitative+Light+Fluorescence>)

and have also been developed to diagnose early caries lesions.¹³

In an in-vitro study, Rodrigues et al.¹⁴ investigated the efficacy of LED and two LF-based devices in detecting occlusal caries. The results demonstrated that LED and LF based devices allow good reproducibility and are more useful tools for detecting early signs of caries than conventional caries diagnosing methods.¹⁴ However, the role of the examiners' experience in detecting early caries using lasers cannot be overruled.

Early diagnosis of caries may help reduce pain, inflammation and economic burden and contribute to enhancing oral health related quality of life¹⁵⁻¹⁷.

Moreover, it allows application of preventive measures to arrest the lesion by avoiding invasive restorative procedures.

Therefore, the aim of the present study was to comprehensively review the various laser-based systems used in early detection of dental caries.

Materials and methods

Focused question

The addressed focused question was "Which lasers-based caries detecting systems are currently available for early diagnosis of caries?"

Study eligibility criteria

The following eligibility criteria were imposed: Clinical studies, case-reports, intervention: efficacy of LF in diagnosing early carious lesions compared to traditional caries detecting techniques and studies published only in English.

Literature search strategy

To address the focused question, PubMed/MEDLINE and Google-Scholar databases were searched from 1995 up to and including June 2015 using different combinations of the following key words: "dental caries", "diagnosis", "laser"; "fluorescence", "phototherapy" and "light". Literature reviews, letters to the Editor and commentaries were excluded. The pattern of the present review was customized to summarize the relevant information.

Results

DIAGNOdent system

The DIAGNOdent system (Figure 1a) uses digital imaging fiber-optic transillumination, which identifies zones of demineralization by recording the transmitted visible light that is directed at the tooth. The concept behind using a laser beam in the diagnosis of caries is that altered mineralized surfaces irradiated by a longitudinal light wave emit fluorescent radiation. The device comprises a probe that emits red light (wavelength 655 nm) directed to the mineralized teeth surface/s under examination. Demineralized teeth surfaces emit a fluorescent light (mainly due to bacterial porphyrins), which is captured back by the probe and the device displays values ranging from 0 to 99.¹⁸ DIAGNOdent has been tested extensively, including for the detection of occlusal and smooth surface caries, comparing its results with visual inspection, histology, radiography and quantitative light-induced fluorescence. However, this device was later updated by a cable free pen-type LF device (LFpen), which additionally allowed approximal surfaces to be examined (DIAGNOdent pen, KaVo, Biberach, Germany) (Figure 1b).

Light-emitting-diode based caries detection

Light-emitting-diode (LED) (MIDWEST Caries ID, MID, Dentsply Professional, York, Pennsylvania) (Figure 2) is a handheld device that aims at detecting caries. The device is based on the concept that demineralized teeth surfaces influence reflection and reflectance of the emitted light.¹⁹ The presence of demineralization changes the LED from green to red with a concurrent audible signal thereby confirming the presence of caries.¹⁹ In this caries detection system, the speed of the signal is associated with the depth of the carious lesion. To our knowledge of indexed literature, there is a scarcity of studies that have assessed the efficacy of LEDs in detecting early caries. A study by Bozdemir et al.¹³ compared the performance of LED-based and LF-based devices with that of visual examination in the diagnosis of occlusal caries. In this study, 156 occlusal surfaces were visually examined for evidence of

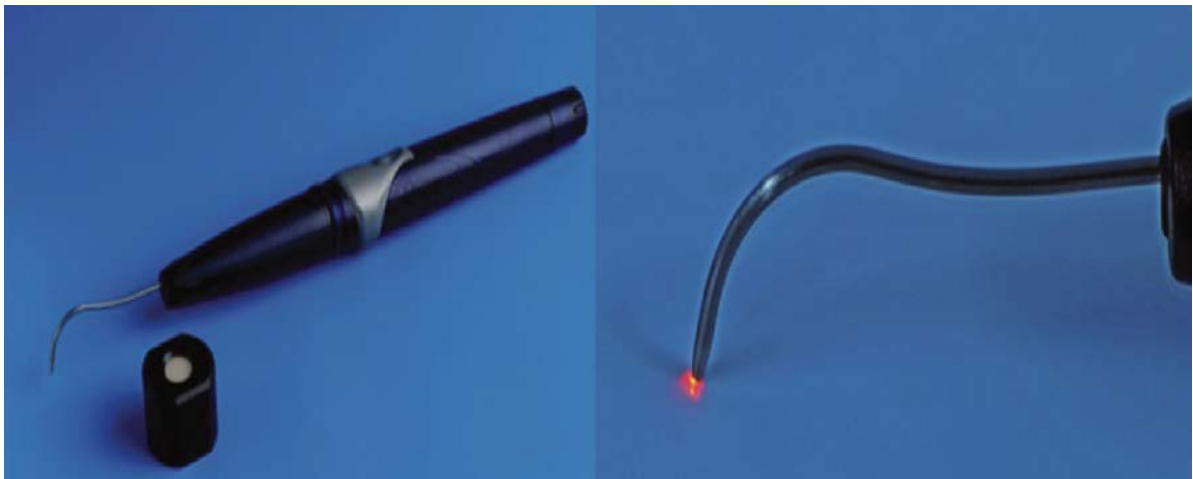

Figure 2. Light emitting diode caries detection system

(Source of image: Rodrigues JA et al. Light-emitting diode and laser fluorescence-based devices in detecting occlusal caries. *J Biomed Opt.* 2011;16(10):107003)

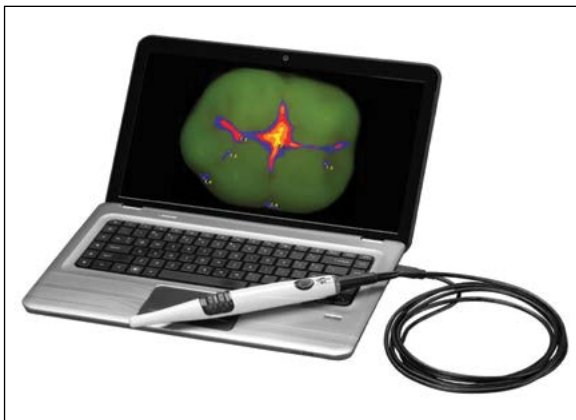


Figure 3. Fluorescence camera based caries detection system

(Source of image: <http://www.airtechniques.com/products/cam-x-spectra-caries-detection-aid.html>)

caries following which they were assessed with the LED- and LF-based caries detection devices¹³. The study concluded that LED-based and LF-based devices detect caries more accurately as compared to traditional visual-examination based methodologies.¹³

However, the result showed no significant difference in the caries detecting efficacy of LED- and LF-based systems.¹³ Results by Rodriguez et al.¹⁴ demonstrated that LED-based caries diagnosis systems are unable to differentiate sound surfaces from enamel caries. In this study¹⁴, the laser parameters used in the LED-based caries detection system remained unclear. In this regard, further studies with a large sample size are needed to assess the significance of LED-based systems in the diagnosis of caries.

Fluorescence cameras

Achilleos et al.²⁰, introduced a fluorescence device (FC; Vista Proof, Duerr Dental, Germany), to detect caries on occlusal surfaces of teeth (Fig.3). The tool emits light with a wavelength of 400 nm and filters the fluorescence emitted by the tissue.

Specific software quantifies the fluorescence on a numerical scale ranging from 0 to 5. This device also works on the same principle as that for DIAGNOdent that is, capturing the fluorescence from bacterial porphyrins.

The authors reported the sensitivity of Vista Proof to be significantly greater than that for DIAGNOdent (pen).²⁰ In another study, Seremidi et al.²¹ compared the efficacy of fluorescence device VistaProof (VP) and DIAGNOdent Pen.

In this study, 107 sites on 41 occlusal surfaces of recently extracted premolars were selected and classified into lesion categories according to Ekstrand's clinical criteria^[21].

The fluorescence of the sites was measured by the Vista Proof and DIAGNOdent Pen devices. The results demonstrated no statistically significant difference between the accuracy of DP and VPs for both enamel and dentin lesions.²¹

Multispectral near-infrared reflectance imaging

Near infrared (NIR) multispectral imaging is a novel non-invasive imaging technology that maps and quantifies caries without using ionizing radiation.²²⁻²⁵

This technology works on the concept that for longer wavelengths (such as 1450 nm), water absorption increases significantly and reduces the penetration of the NIR light (Fig.4).²⁶

NIR digital imaging transillumination technology has been shown to be useful as a diagnostic tool in the detection of proximal caries and, less importantly, for occlusal caries, fissures, and secondary decay around amalgam and composite restorations.²⁵

It has also been reported that early demineralization appears with high contrast at NIR wavelengths due to a 10- to 20-fold difference in the magnitude of light scattering between sound and demineralized enamel.^{22,26}

In an in-vitro study, Simon et al.²⁶ assessed how the lesion contrast changes with the lesion severity and depth for different spectral regions in the NIR

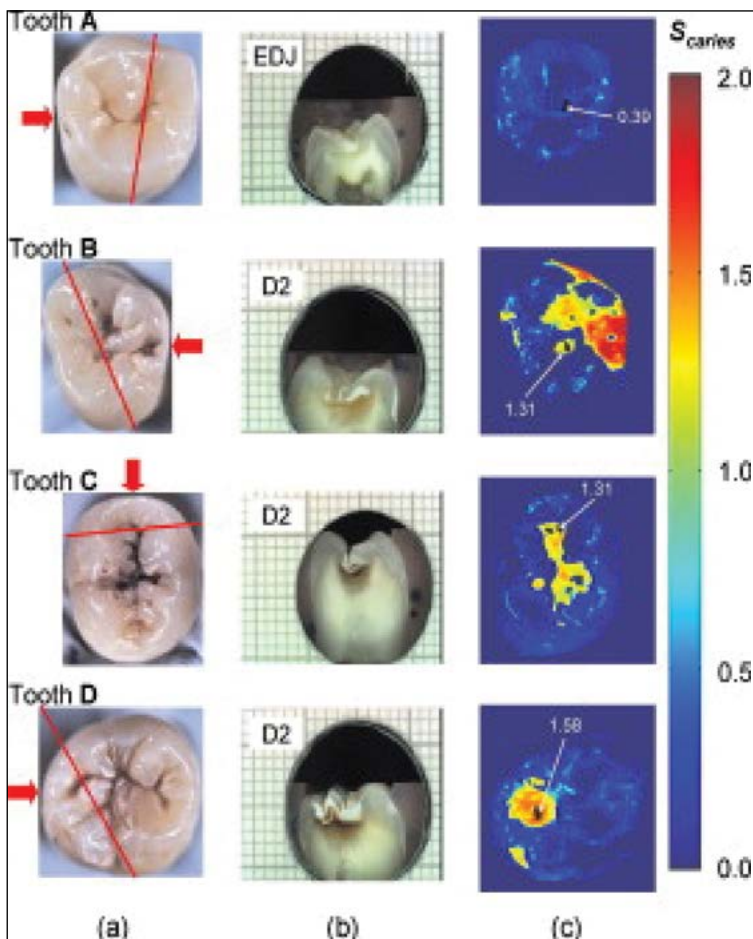


Figure 4. Multispectral near-infrared reflectance imaging: (a) clinical presentation of caries on the tooth; (b) cross-section of tooth with caries; (c) Multispectral near-infrared reflectance imaging

(Source of image: Zakian C et al. Near-infrared hyperspectral imaging of teeth for dental caries detection. *J Biomed Opt.* 2009;14(6):064047)

and compared that range of contrast with visible reflectance and LF. Forty-four human molars were painted with an acid-resistant varnish leaving a window (4mm×4mm) on the occlusal surface of each tooth exposed for demineralization.

In the unprotected windows, artificial lesions were induced using a demineralizing solution at pH 4.5. Near-IR reflectance images were obtained over several near-IR spectral distributions, visible light reflectance and LF with 405 nm excitation and detection at wavelengths greater than 500 nm. In each sample, the severity of the demineralization window was non-invasively assessed using cross polarization optical coherence tomography (CP-OCT).

The CP-OCT results showed that the severity of the carious lesions varied significantly across the sample windows and that visible light does not precisely reflect the large variation in the lesion severity as compared to near-IR reflectance. Reflectance measurements at certain near-IR wavelengths have been reported to more accurately reflect variation in the depth and severity of the lesions.²⁷ Chung et al.²⁷ reported that near-IR measurements at higher wavelengths (1,200nm to 1,600nm) reflect the variation in the depth and severity of the lesions more accurately as compared to shorter wavelengths.

In another study, Wu and Fried²⁸ compared the image contrast of artificial carious lesions

produced on the buccal and occlusal surfaces of teeth using fluorescence, visible reflectance and near-IR reflectance.

The results demonstrated that near-IR reflectance at wavelength 1,310-nm yielded the greatest contrast than visible reflectance though it remained statistically comparable with fluorescence imaging.²⁸

In a recent study Söchtig et al.²⁹ suggested that NIR transillumination is a method that may help avoid bitewing radiographs for diagnosis of caries in routine dental practice.

However, further studies over a greater range of lesion severity are needed to determine the optimum performance ranges for this imaging technique.

Conclusion

Lasers-based caries systems are useful tools in the early detection of caries as compared to traditional visual and radiographic examination techniques; however, further studies are needed to assess the caries diagnostic efficacy of the various commercially available laser-based caries diagnostic systems.

Conflict of interest and financial disclosure

The authors declare that they have no conflict of interest and there was no external source of funding for the present study.

Bibliography

1. Nakornchai S, Atsawasuwan P, Kitamura E, Surarit R, Yamauchi M. Partial biochemical characterisation of collagen in carious dentin of human primary teeth. *Arch Oral Biol.* 2004;49(4):267-273.
2. Ekstrand KR, Ricketts DN, Kidd EA. Occlusal caries: pathology, diagnosis and logical management. *Dent Update.* 2001;28(8):380-387.
3. Ricketts DN, Ekstrand KR, Kidd EA, Larsen T. Relating visual and radiographic ranked scoring systems for occlusal caries detection to histological and microbiological evidence. *Oper Dent.* 2002;27(3):231-237.
4. Bader JD, Shugars DA, Bonito AJ. A systematic review of the performance of methods for identifying carious lesions. *J Public Health Dent.* 2002;62(4):201-213.
5. Omura Y, Lorberboym M, Beckman S. Radiation injury & mercury deposits in internal organs as a result of thallium-201 chloride intravenous injection for SPECT imaging; additional biochemical information obtained in the images of organs from SPECT or PET scans; & potential injury due to radiation exposure during long distance flights. *Acupunct Electrother Res.* 1995;20(2):133-148.
6. Yuan MK, Tsai DC, Chang SC, Yuan MC, Chang SJ, Chen HW, Leu HB. The risk of cataract associated with repeated head and neck CT studies: a nationwide population-based study. *AJR Am J Roentgenol.* 2013;201(3):626-630.
7. Haiter-Neto F, Wenzel A, Gotfredsen E. Diagnostic accuracy of cone beam computed tomography scans compared with intraoral image modalities for detection of caries lesions. *Dentomaxillofac Radiol.* 2008;37(1):18-22.
8. Oancea R, Podariu AC, Vasile L, Sava-Rosianu R, Folescu R. In vitro evaluation of laser fluorescence devices for caries detection through stereomicroscopic imaging. *Rom J Morphol Embryol.* 2013;54(2):333-341.
9. Venugopal C, Nazeer SS, Balan A, Jayasree RS. Autofluorescence spectroscopy augmented by multivariate analysis as a potential noninvasive tool for early diagnosis of oral cavity disorders. *Photomed Laser Surg.* 2013;31(12):605-612.
10. Takamori K, Hokari N, Okumura Y, Watanabe S. Detection of occlusal caries under sealants by use of a laser fluorescence system. *J Clin Laser Med Surg.* 2001;19(5):267-271.
11. Lussi A, Megert B, Longbottom C, Reich E, Francescut P. Clinical performance of a laser fluorescence device for detection of occlusal caries lesions. *Eur J Oral Sci.* 2001;109(1):14-19.
12. Costa AM, Yamaguti PM, De Paula LM, Bezerra AC. In vitro study of laser diode 655 nm diagnosis of occlusal caries. *ASDC J Dent Child.* 2002;69(3):249-253, 233.
13. Bozdemir E, Karaarslan ES, Ozsevik AS, Ata Cebe M, Aktan AM. In vivo performance of two devices for occlusal caries detection. *Photomed Laser Surg.* 2013;31(7):322-327.
14. Rodrigues JA, Hug I, Neuhaus KW, Lussi A. Light-emitting diode and laser fluorescence-based devices in detecting occlusal caries. *J Biomed Opt.* 2011;16(10):107003.
15. Verdonschot EH, Angmar-Mansson B, ten Bosch JJ, Deery CH, Huysmans MC, Pitts NB, Waller E. Developments in caries diagnosis and their relationship to treatment decisions and quality of care. ORCA Saturday Afternoon Symposium 1997. *Caries Res.* 1999;33(1):32-40.
16. Ramos-Jorge J, Pordeus IA, Ramos-Jorge ML, Marques LS, Paiva SM. Impact of untreated dental caries on quality of life of preschool children: different stages and activity. *Community Dent Oral Epidemiol.* 2014;42(4):311-322.
17. Huang DL, Chan KC, Young BA. Poor oral health and quality of life in older U.S. adults with diabetes mellitus. *J Am Geriatr Soc.* 2013;61(10):1782-1788.
18. Braga MM, Mendes FM, Ekstrand KR. Detection activity assessment and diagnosis of dental caries lesions. *Dent Clin North Am.* 2010;54(3):479-493.
19. Strassler HE, Sensi LG. Technology-enhanced caries detection and diagnosis. *Compend Contin Educ Dent.* 2008;29(8):464-465, 468, 470 passim.
20. Achilleos EE, Rahiotis C, Kakaboura A, Vougiouklakis G. Evaluation of a new fluorescence-based device in the detection of incipient occlusal caries lesions. *Lasers Med Sci.* 2013;28(1):193-201.
21. Seremidi K, Lagouvardos P, Kavvadia K. Comparative in vitro validation of VistaProof and DIAGNOdent pen for occlusal caries detection in permanent teeth. *Oper Dent.* 2012;37(3):234-245.
22. Salsone S, Taylor A, Gomez J, Pretty I, Ellwood R, Dickinson M, Lombardo G, Zakian C. Histological validation of near-infrared reflectance multispectral imaging technique for caries detection and quantification. *J Biomed Opt.* 2012;17(7):076009.
23. Staninec M, Douglas SM, Darling CL, Chan K, Kang H, Lee RC, Fried D. Non-destructive clinical assessment of occlusal caries lesions using near-IR imaging methods. *Lasers Surg Med.* 2011;43(10):951-959.
24. Fried D, Featherstone JD, Darling CL, Jones RS, Ngathheppitak P, Bühler CM. Early caries imaging and monitoring with near-infrared light. *Dent Clin North Am.* 2005;49(4): 771-793, vi.
25. Abdelaziz M, Krejci I. DIAGNOcam--a Near Infrared Digital Imaging Transillumination (NIDIT) technology. *Int J Esthet Dent.* 2015;10(1):158-165.
26. Simon JC, Chan KH, Darling CL, Fried D. Multispectral near-IR reflectance imaging of simulated early occlusal lesions: Variation of lesion contrast with lesion depth and severity. *Lasers Surg Med.* 2014;46(3):203-215.
27. Chung S, Fried D, Staninec M, Darling CL. Near infrared imaging of teeth at wavelengths between 1200 and 1600 nm. *Proc SPIE Int Soc Opt Eng.* 2011;7884. pii:78840X.
28. Wu J, Fried D. High contrast near-infrared polarized reflectance images of demineralization on tooth buccal and occlusal surfaces at $\lambda = 1310\text{-nm}$. *Lasers Surg Med.* 2009;41(3):208-213.
29. Söchtig F, Hickel R, Kühnisch J. Caries detection and diagnostics with near-infrared light transillumination: clinical experiences. *Quintessence Int.* 2014; 45(6): 531-538.

Fawad Javed

DDS, DMD, PhD, Research Associate
Division of General Dentistry, Eastman Institute for Oral Health
University of Rochester, NY, USA



CV

Dr. Fawad Javed completed his doctoral education and post-doctoral training at the Department of Dental Medicine, Karolinska Institutet, Stockholm, Sweden. Dr. Javed has published over 90 articles in ISI-indexed medical and dental journals. Presently, Dr. Javed is a postdoctoral fellow and Research Associate at the Division of General Dentistry, Eastman Institute for Oral Health, University of Rochester, NY, USA. Dr. Javed's research interests include oral oncology research, the connection between oral inflammatory disorders and systemic conditions particularly diabetes mellitus, the impact of smoking and use of smokeless tobacco on oral health, the cytokine profile in serum and oral fluids in patients with and without systemic conditions, implant dentistry, bone regeneration research and saliva research. Dr. Javed is a member of the Editorial board and also a member of peer-review panels of various indexed medical and dental journals.

Questions

Dental caries are caused by the action of cariogenic bacteria on:

- a. Soluble proteins;
- b. Fermentable carbohydrates;
- c. Lactose;
- d. Teeth.

Traditionally, caries are diagnosed by:

- a. X-rays;
- b. Computed tomography;
- c. Lasers;
- d. Visual examination.

One factor that makes light-emitting-diode and light fluorescence beneficial in the early detection of dental caries is:

- a. Both are inexpensive;
- b. Both produce good reproducibility;
- c. Both are technique sensitive;
- d. Both are surgical lasers.

The DIAGNodent system uses _____ for caries detection:

- a. digital imaging fiber-optic transillumination;
- b. digital imaging xrays;
- c. ultrasonic waves;
- d. none of the above.