

# HEADACHE - AN INTERDISCIPLINARY PROBLEM ASPECTS OF DENTAL FUNCTIONAL DIAGNOSTICS AND THERAPY

[https://doi.org/10.25241/stomaeduj.2014.1\(1\).art.6](https://doi.org/10.25241/stomaeduj.2014.1(1).art.6)

## Abstract

**Aim:** Craniofacial pain is one of the most common disorders affecting the general population. The aim of this article is to show the importance of interdisciplinary approach in solving complicated cases with headache and atypical facial pain.

**Summary:** Two case reports are presented, with severe craniofacial pain, with underlying intricate causes. The case of a 23 aged female with tension headaches, bilateral tinnitus and atypical facial pain, but also with anterior open bite from premolars who was admitted to a neurological clinic, was finally resolved only after a splint therapy. The other case was a 42 year old woman with severe unilateral facial pain, caused by an endometric tissue from maxillary bone that produced multiple hollows or cavities in the adjacent teeth. The pain was alleviated after teeth extractions and appropriate hormonal therapy.

**Key learning points:** Because headache causes are manifold, diagnostics and therapy require an interdisciplinary medical approach.

From the dental and maxillofacial standpoint, diseases and disorders of the teeth, periodontium, other craniofacial hard and soft tissues, as well as craniomandibular dysfunction (CMD) must be taken into consideration in treating such patients.

**Keywords:** unspecific headache, tension headache, muscle relaxation, craniomandibular dysfunction, Michigan splint

## Introduction

The reasons for acute and chronic craniofacial pain can be extremely diverse. An exact identification of causes is often impossible without close cooperation between various medical disciplines, and monocausal treatment approaches to pain relief are often unsatisfactory (1,2,3). Understanding these multilayered symptoms is fundamentally made more difficult due to the great diversity and inherently variable risk factors that may play a role (4,5). They frequently occur in combination, and interactions arise with complex amplifying effects, so that scientific studies require particularly great, interdisciplinary efforts.

In the past, the fields of dentistry and oral medicine have, for different reasons, not always played a sufficient role in the treatment of craniofacial pain, although experienced pain therapists have long demanded including the dental/oral medicine sector in the diagnostics and treatment of such disorders (Fig. 1). Although craniomandibular dysfunctions (CMD) are the focus of this article, it should be mentioned that irritations and diseases of the pulp, periodontium, glands, nasal sinuses, and other hard and soft tissues in the craniofacial area including space-occupying processes/structures such as tumors can cause comparable craniofacial pain, which is sometimes erroneously interpreted as a functional disorder and treated with, for instance, occlusal splints.

Given this background, failed splint therapy should not be blamed on the method, but rather on the differential diagnostic exclusion of masticatory functional causes of the respective symptoms. Recent controlled studies unambiguously show that with individually adjusted centric splints (Michigan splints), significant improvements result in the therapy of CMD, especially compared to merely vacuum-drawn, non-individualized

### Cite this article:

Meyer GB, Bernhardt O, Küppers A. Headache - an interdisciplinary problem. Aspects of dental functional diagnostics and therapy. Stoma Edu J. 2014; 1(1):33-40.

### Georg B. Meyer<sup>1a\*</sup>, Olaf Bernhardt<sup>2b</sup>, Arnd Küppers<sup>2c</sup>

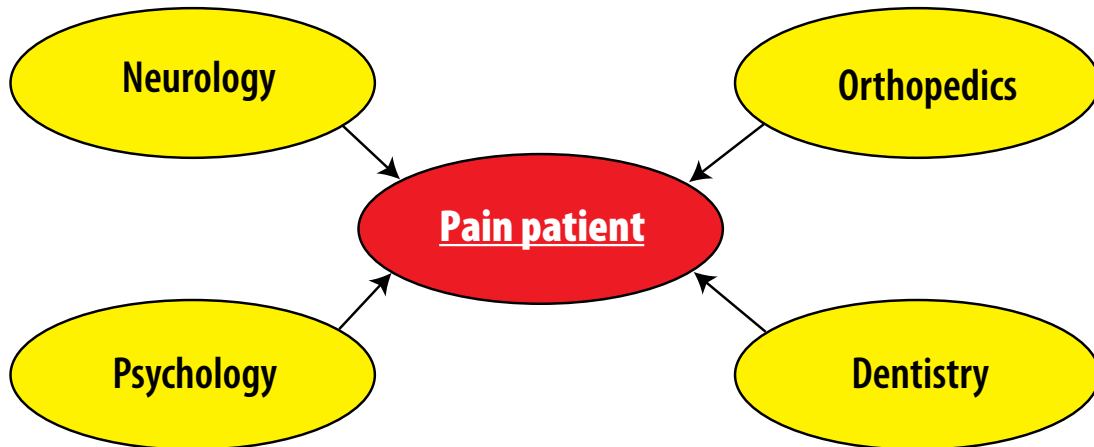
1. Zentrum für Zahn-, Mund-, und Kieferheilkunde  
Universitätsmedizin Greifswald,  
Greifswald, Germany  
2. Poliklinik für Zahnerhaltung,  
Parodontologie und  
Endodontologie  
Universitätsmedizin Greifswald,  
Greifswald, Germany  
a. DMD, PhD, Dr hc, Professor  
and Chairman  
b. DMD, PhD, Professor  
c. DMD, PhD

Received: 17 October 2013  
Accepted: 07 January 2014

### \* Corresponding author:

Professor Georg B. Meyer, DMD, PhD, Dr hc, Chairman  
Zentrum für Zahn-, Mund- und Kieferheilkunde,  
Ernst-Moritz-Arndt Universität,  
Rotgerberstraße 8, D-17475  
Greifswald, Germany.  
Tel: +493834867130,  
Fax: +493834867171.  
e-mail: gemeyer@uni-greifswald.de

## Multi-/interdisciplinary approach



U.T. Egle, Psychosomatik/Psychotherapie

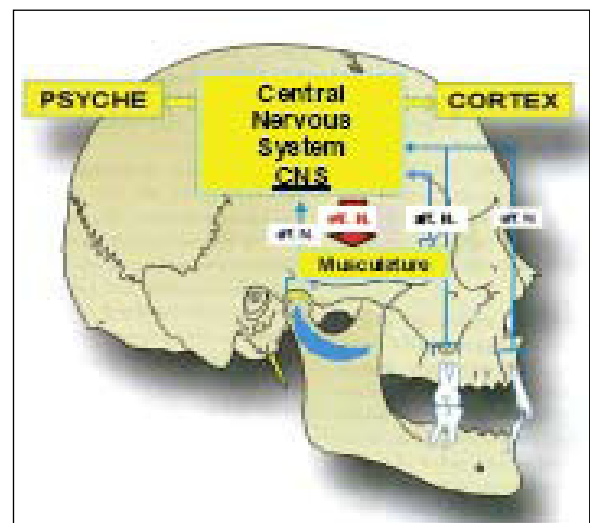
**Figure 1.** For patients with chronic headache, dental diagnostic and therapy are as valuable as that of other disciplines (taken from Egle, Mainz, 2000)

splints (6). Significant associations between CMD and frequent headaches were demonstrated in an epidemiological survey of over 4000 subjects in the Study of Health in Pomerania (SHIP) (4).

In a diagnostically and therapeutically oriented dental follow-up study of patients whom neurologists and neurosurgeons had diagnosed with trigeminal neuralgia, Lotzmann et al. (7) found that in up to 50 % of the cases, CMD was the true cause of the neuralgic symptoms. Interestingly, over 70 % of these cases presented infraocclusion in the posterior dentition in centric relation, which was often the result of prostheses with insufficient height or orthodontic treatment.

Craniofacial pain is frequently accompanied by temporomandibular joint (TMJ) and otological symptoms (8). The SHIP study showed correlations between tinnitus and CMD (9). Evaluating 200 CMD patients who simultaneously suffered from tinnitus, earache, and dizziness, Wright (8) found that after successful treatment of masticatory functional disorders, these associated symptoms improved significantly.

While interactions between CMD and unspecific headaches, tension headaches, and trigeminal neuralgia have been proven (4,7,10), the dental contribution to the etiology of migraine or migraine-like pain is controversial. Based on individual instances of successful dental treatment, particularly in cases of migraine symptoms unchangingly confined to one half of the face, some neurologists recommend a clinical dental consultation (11,12,13,14).

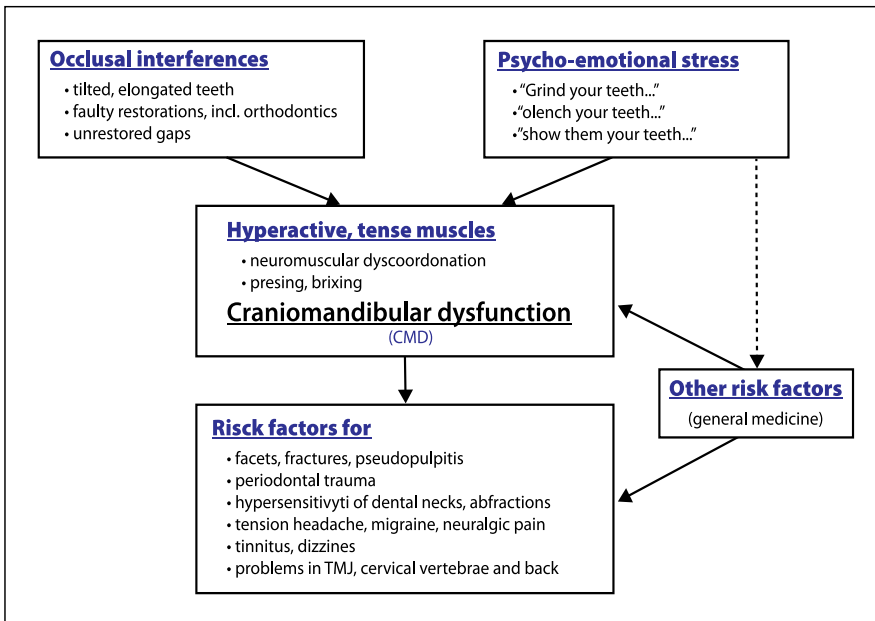


**Figure 2.** In the Physiology of a healthy masticatory organ is characterized by receptors in the teeth, periodontium, muscles, and TMJs that transmit signals about the current status via afferent nerves (aff.N.) to the central nervous system. Based on this sensory information, a synaptic transformation to movement follows. Along efferent nerves (eff.N.), the corresponding motoric units of the musculature are activated, so that all masticatory functions can run in a coordinated manner

### **Masticatory functional aspects**

#### **Physiology**

During the growth of a healthy masticatory organ, the occlusal structures of all teeth and the TMJ adapt themselves to each other to follow a uniform geometry. Starting



**Figure 3.** Dental risk factors for CMD are mainly occlusal interferences and/or psycho-emotional stress

<b>Finding:</b>	<b>Yes</b>	<b>No</b>
1. Mouth opening asymmetrical	<input type="checkbox"/>	<input type="checkbox"/>
2. Mouth opening limited	<input type="checkbox"/>	<input type="checkbox"/>
3. Traumatic eccentric movements	<input type="checkbox"/>	<input type="checkbox"/>
4. TMJ noises, pain	<input type="checkbox"/>	<input type="checkbox"/>
5. Muscle palpation (M. masseter temporalis) asymmetrically positive finding	<input type="checkbox"/>	<input type="checkbox"/>
<b>Evaluation</b>		
• max. 1 pos. finding: health probable	<input type="checkbox"/>	<input type="checkbox"/>
• 3 or more pos. findings: disease probable	<input type="checkbox"/>	<input type="checkbox"/>
<b>Supplemental finding</b>		
6. Physiological centric position unequal max. intercuspation "Cotton-Roll-Test" (early contacts, occlusal gliding, enamel chipping, grinding facettes, wedge-shaped defects, tooth mobility, tongue impressions etc.)	<input type="checkbox"/>	<input type="checkbox"/>
<b>Evaluation</b>		
• With pos. finding: disease probable		

**Figure 4.** The Ahlers and Jakstat clinical summary report for CMD risk identification was extended by a test of physiological centric position

from maximum occlusion in which the TMJ structures are also centered, the interplay of cusps and fissures of antagonistic teeth is characterized by the disturbance-free course of all eccentric movements (Fig. 2). Receptors in the teeth, periodontium, muscles, and TMJs are connected by afferent nerves to the central nervous system, and transmit signals about the given status, e.g., the consistency and location of the to-be-chewed food near or on the teeth. Based on this sensory information, a synaptic transformation to movement follows. Along efferent nerves, the corresponding motoric units of the musculature are activated, so that all masticatory functions can run in a coordinated

manner. Psychological and cortical interactions are possible (15).

The mandible assumes the physiological centric relation or "zero position" to the maxilla when protractors as well as retractors are maximally relaxed, and the integral of all muscle activity is thus at the lowest level (16). In this position, maximum intercuspation is possible as long as there are no occlusal interferences. By activating the retractors, about 90% of all adults can perform a tooth-guided, ca. 1 to 3 mm mandibular retral limit movement from centric position, which was formerly known as the retral contact position and erroneously considered to be the same as centric relation (16,17).

**Table 1.** Extra - and intra-oral findings

**The following extra-oral findings were recorded:**

- mandibular mobility, i.e., opening, protrusion, and lateral movements unrestricted and normal;
- palpation pain in both TMJs;
- pressure sensitive musculature in right anterior Temporalis, left Masseter, right shoulder muscles;
- hypersensitive nerve exit points in left infraorbital area, right mandible.

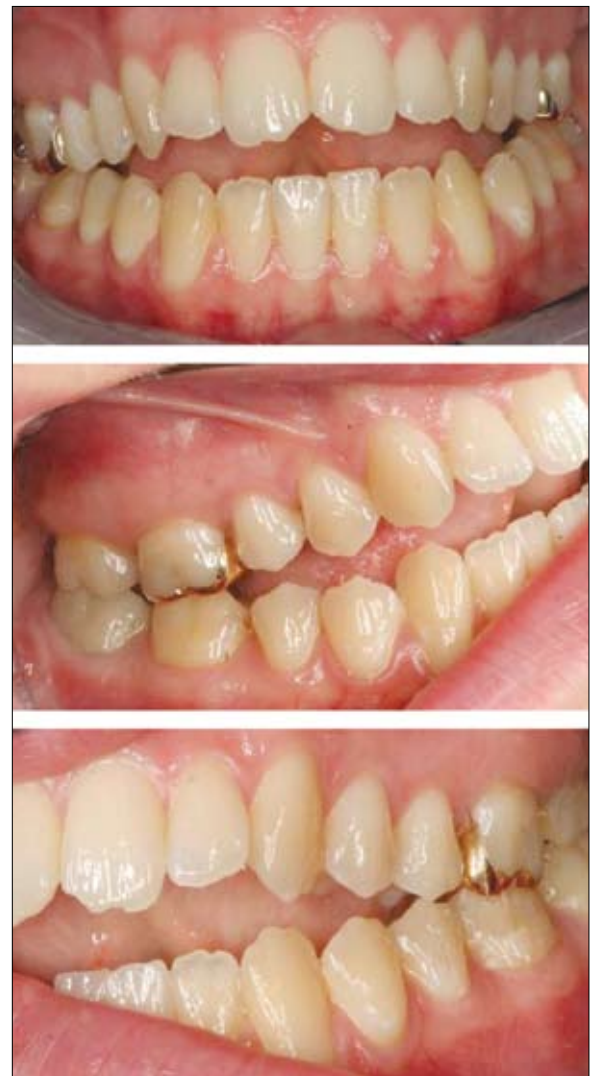**The following intra-oral findings were recorded (Figs 5 to 7):**

- complete, well-maintained dentition without wisdom teeth;
- partial crowns on 16 and 26, gold, with composite fillings on 17,14,24,25,27,37,36,46, and 47;
- suspected dentin fracture in tooth 17;
- bilateral tongue impressions;
- anterior open bite from/to premolars bilaterally;
- premature contacts 17/47 in physiological centric position/cotton-roll test centric.

**Pathology**

Masticatory functional disorders are primarily caused by occlusal discrepancies when these are noticeably above or below the 10- to 20- $\mu$ m range of desmodontal tactility (18). In experimental examinations, Kobayashi and Hansson (19) found that premature occlusal contacts of a magnitude of 100  $\mu$ m on fillings, i.e., 10 times the desmodontal tactility, can contribute to increased muscle activity, bruxism, sleep disorders, increased adrenaline excretion, sleep apnea, TMJ complaints etc. An essential, even decisive exacerbating factor is psycho-emotional stress ("grinding your teeth"); thus, the initial dental diagnostics must pay particular attention to such symptoms (5,10,11,20). The same is true of primarily orthopedic problems which can have an immediate interaction with CMD (17,21).

From a scientific point of view, it is not primarily the occlusal disturbance but rather the hyperactive, pressure-sensitive masticatory and craniofacial muscles which are a significant correlate for the neuromuscular dyscoordination or CMD (Fig. 3). But the grosser occlusal interferences are, the higher is their risk potential for causing CMD (22). Therapeutically, every treatment that leads to muscle relaxation or re-coordination of the neuromuscular system makes sense, for instance, treatment with a dental (relaxation) splint (23,24), information consulting, self-observation, physiotherapy, medication, psychotherapy, and other forms of treatment (5,15,20,25,26).



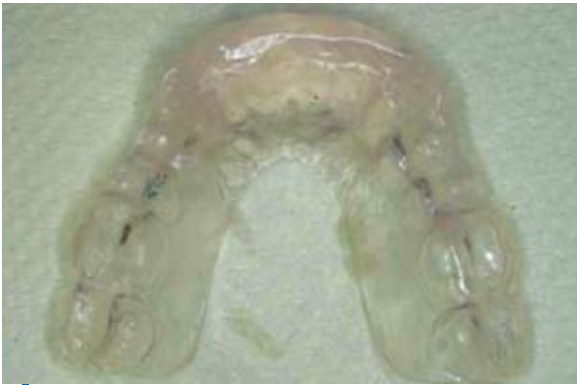**Figure 5-7.** Open bite despite orthodontic treatment, with support exclusively on the molars, which could explain the pain in these areas

**Patient examination**

As part of the interdisciplinary diagnostics of craniofacial pain patients, the anamnesis must determine whether a dental risk exists. After taking the general dental findings, it has proven effective to perform a CMD screening (11), that is, a scientifically founded clinical summary report to determine masticatory functional risk factors. We have added a diagnostic test of physiological centric relation (cotton-roll test) to this screening (13,17) (Fig. 4). These are yes-or-no findings, quickly determined, which very reliably identify CMD patients, for whom more comprehensive diagnostics and therapy must then be performed (11,12).

In the following, two patient cases of craniofacial pain are documented, from which an exact description of the practical dentally recommended diagnostic steps has been omitted. The same goes for the therapeutic clinical concept based on the centric (Michigan) splint, supplemented with adjunct treatment such as instructions for





**Figure 8.** Individual centric splint made in the articulator

self-observation, relaxation, and muscle massage, as these steps and concepts were previously described.

## Case report 1

### Patient history

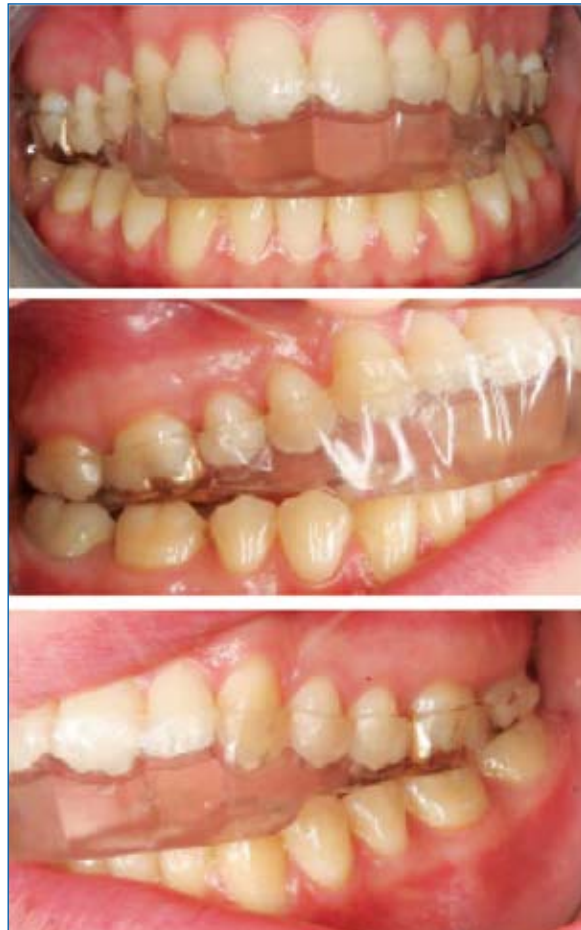A 23-year-old female patient presented at our clinic with intermittent tension headaches, which had otherwise only occurred in the right half of the face, but were now present both right and left. Particularly under tension and stress, bilateral tinnitus also arose, in addition to pain in the maxillary molar region and sinus chiefly on the right side. Examination by an ear-nose-throat doctor found no cause. The patient reported having undergone orthodontic treatment from the age of 11 to 15 years.

At the age of 17, extreme atypical pain in the right half of the face arose, for which the patient was admitted to the neurology department of a clinic. When no cause was found there, she was moved to a psychosomatic clinic. Meanwhile, severe pain arose in the left half of her face. During the subsequent 4-week stay at a pain clinic (Mainz, Germany), dental findings were taken for the first time during an interdisciplinary consultation.

This led to initiating splint therapy, which finally – after her 8-month ordeal – alleviated her pain (Fig. 8-11, Table.1) and let her live a normal life. She visited our clinic because the original splint was worn out and the headaches, maxillary pain, and tinnitus had returned.

### Therapy

After providing the patient with educational information, instructions on self-observation, relaxation, and muscle massage, an exercise DVD (20,25), and a calculation of costs, splint therapy was performed. Subsequent to impression taking of the maxilla and mandible

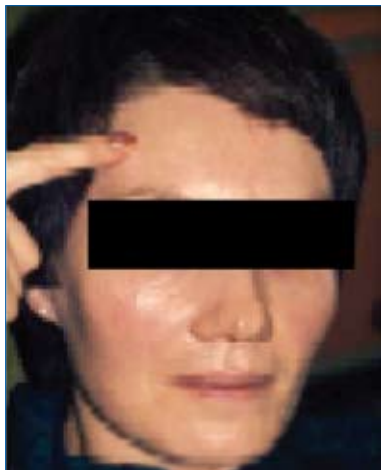

**Figure 9-11.** The splint creates an individual balance of the bite position in all quadrants. The patient became symptom-free

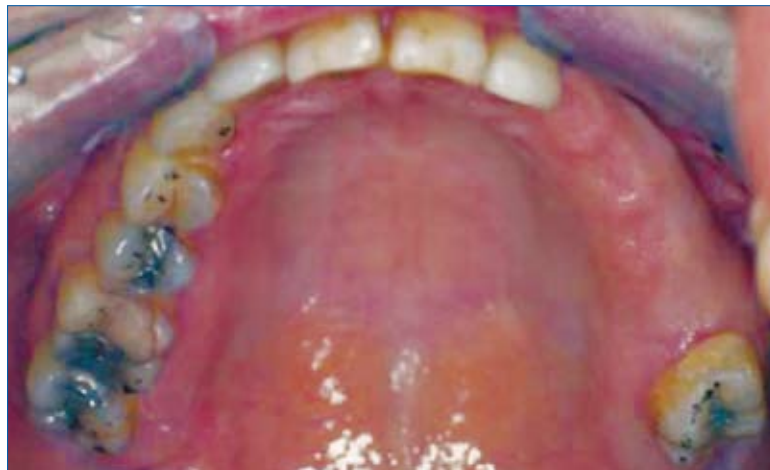and pouring the models, the facebow and protrusion registration were placed in the articulator with the help of the clinical centric registration of both jaws so that it corresponded to the clinical situation. As expected, even after placement in the articulator, centric premature contacts were found on teeth 17 and 47, which indicated that the working steps had been done correctly. Using a hard, 1.5-mm-thick piece of composite foil, a vacuum-drawn splint was constructed and individually corrected in the articulator – according to the occlusal concept of the Michigan splint – first by grinding and then by applying composite on certain sites in order to create equal support in all quadrants and canine guidance during excentric movements (Figs 8 to 11).

### Wearing instructions/Follow-up

During the initial treatment phase, the splint should be worn as much as possible, i.e., both day and night. Exceptions can be made for eating and lengthy periods of speech such as during presentations etc. The patient should be informed that after overcoming initial awkwardness, accustomization occurs within just a few days



**Figure 12.** This patient periodically had severe pain attacks in the right facial half



**Figure 13.** Even after extraction of teeth 13 to 16 from the pre-viously fully dentate maxilla, no improvement of symptoms occurred in that side of the face (mirror image photo)

(even faster for mandibular splints), providing considerable relief. It is necessary to perform the first follow-up after 3 or 4 days. After "cotton-roll relaxation", any corrections required will be done to ensure equal support in all quadrants. Only when this support remains stable can the follow-up intervals be lengthened.

The patient introduced here was symptom-free again after just a few weeks. It may be recommendable to shorten the splint wearing time, for instance, using it only in particular stressful situations. When not in use, the splint should be stored under moist conditions to avoid drying out and thus deforming and becoming brittle.

## Case report 2

### Patient history

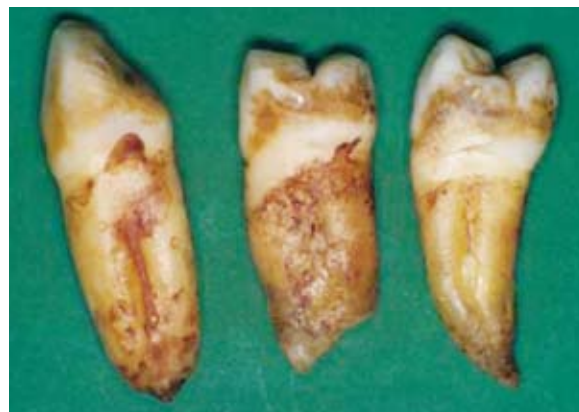A 42-year-old patient presented with periodic, severe headache attacks limited to the right side of her face (Fig. 12). Neurological and otorhinolaryngological examination had found no cause.

### Findings

Asymmetrical tension in the masticatory and shoulder-muscle areas. Mandibular mobility was not restricted, but deflection to the right was observed upon mouth opening. Except for wisdom teeth, the patient was completely dentate. The only restorations were some mid-sized amalgam fillings in the posterior teeth. In centric position (cotton-roll test), equal support was found in all quadrants.

### Therapy

Relaxation splint therapy was conducted, which the patient found very pleasant and helpful and completely alleviated the pain. The well-fitting



**Figure 14.** On the roots of the extracted teeth, hollows or cavities are visible, which are perhaps related to extra-genital endometriosis

splint remained stable, and no further occlusal corrections were necessary.

Surprisingly, the patient returned after ca. 4 weeks with facial pain so severe that we had to have her admitted to the University Clinic's pain station. Symptomatic medication relieved the pain, but no cause for it could be found. Examinations at the dental clinic, also conducted by oral and maxillofacial surgeons and the dental radiology department, discovered multiple hollows or cavities in the maxillary lateral teeth of the face-half affected; teeth 13, 14, and 15 were thus extracted (Figs 13 and 14). In spite of this, the severe unilateral facial pain returned almost exactly 4 weeks later.

Finally, it was the patient's physician who suspected menstrual cycle involvement and referred her to the gynecology clinic. There, the rare but correct diagnosis of extragenital endometriosis was made. During embryonic development, endometrial tissue had scattered into the right half of the face and later became active once a month, causing facial pain. Appropriate hormonal treatment alleviated the symptoms.

## Conclusion

Both current research and the patient cases presented here clearly demonstrate the need for the fields of dentistry and oral medicine to become more involved in answering interdisciplinary medical questions, as was expressly demanded by Germany's Council of Sciences in its 2005 declaration on the future of dentistry.

Epidemiological data suggest that many who suffer from craniofacial pain can be helped by dental diagnostics and therapy, so that an interdisciplinary examination of craniofacial pain without considering the oral/dental aspects is unjustifiable (see Fig. 1).

In terms of costs, it makes sense for health insurance to reimburse the diagnostic and therapeutic measures provided by our discipline in cases such as those described here, thus motivating dental professionals to get involved, especially considering the fact that misdirected treatment by other medical disciplines and the associated increase in sick-leave are ultimately much more expensive, as the first patient case described above shows. At the very least, state health insurance should finance the rapidly performed yet very informative clinical summary report on CMD risk for every patient, since this would probably ultimately save a great deal of money elsewhere.

## Bibliography

1. Ash MM. Schienentherapie. München-Jena: Urban & Fischer Verlag; 2006.
2. Göbel H. Erfolgreich gegen Kopfschmerzen und Migräne. Aufl. Berlin: Springer; 2002.
3. Slavicek R. Das Kauorgan: Funktionen und Dysfunktionen. Klosterneuburg: Gamma-Verlag; 2000.
4. Bernhardt O, Gesch D, Mundt T, Mack F, Schwahn C, Meyer G, Hensel E, John U. Risk factors for headache, including TMD signs and symptoms, and their impact on quality of life. Results of the Study of Health in Pomerania (SHIP). Quintessence Int. 2005; 36(1):55-64.
5. Graber G. Der Einfluss von Psyche und Stress bei funktionsbedingten Erkrankungen des stomatognathen Systems. In: Funktionsstörungen des Kauorgans. Hrsg.: B. Koeck. München: Urban & Schwarzenberg; 1995.
6. Ekberg E, Vallon D, Nilner, M. The efficacy of appliance therapy in patients with temporomandibular disorders of mainly myogenous origin. A randomized, controlled, short-term trial. J Orofac Pain. 2003; 17(2):133-139.
7. Lotzmann U, Vadokas V, Steinberg JM, Kobes L. Dental aspect of the differential diagnosis of trigeminal neuralgia. J Gnathol. 1994; 13(1):15-22.
8. Wright EF. Otologic symptom improvement through TMD therapy. Quintessence Int. 2007; 38(9):e564-571.
9. Bernhardt O, Gesch D, Schwahn C, Bitter K, Mundt T, Mack F, Kocher T, Meyer G, Hensel E, John U. Signs of temporomandibular disorders in tinnitus patients and in a population-based group of volunteers: results of the Study of Health in Pomerania. J Oral Rehabil. 2004; 31(4):311-319.
10. Kreyer G. Das Orofazialsystem als Schnittstelle zwischen Psyche und Soma. Zahnärztl Mitt 2005; 95(6):1366-1371.
11. Ahlers MO, Jakstat HA. Klinische Funktionsanalyse. Hamburg: Denta Concept Verlag; 2007
12. Freesmeyer WB. Zahnärztliche Funktionstherapie. München Wien: Carl Hanser Verlag; 1993.
13. Meyer G, Bernhardt O, Asselmeyer T. Schienentherapie heute. Quintessenz. 2007; 58(5):489-500.
14. Franco AL, Goncales DA, Castanharo SM, Speciali JG, Bigal ME, Camparis CM. Migraine is the most prevalent primary headache in individuals with temporomandibular disorders. J Orofac Pain. 2010; 24(3):287-292.
15. Kindler S, Samietz S, Houshmand M, Grabe HJ, Bernhardt O, Biffar R, Kocher T, Meyer G, Völzke H, Metelmann HR, Schwahn C. Depressive and anxiety symptoms as risk factors for temporomandibular joint pain: a prospective cohort study in the general population. J Pain. 2012; 13(12):1188-1197.
16. Meyer G. Die physiologische Zentrik im Rahmen der instrumentellen Okklusionsdiagnostik. In: Funktionslehre. Schriftenreihe APW. München: Carl Hanser; 1993.
17. Lotzmann U. The effect of divergent positions of maximum intercuspation on head posture. J Gnath. 1991; 10(1):63-68.
18. Utz KH. Untersuchungen über die interokklusale taktile Feinsensibilität natürlicher Zähne mit Hilfe von Aluminium-Oxid-Teilchen. Dtsch Zahnärztl Z. 1986; 41(3):313-315.
19. Kobayashi Y, Hansson TL. Auswirkungen der Okklusion auf den menschlichen Körper. Phillip J Restaur Zahnmed. 1988; 5(5):255-263.
20. Schulte W. Die exzentrische Okklusion. Berlin: Quintessenz; 1983.
21. Fu AS, Mehta NR, Forgione AG, Al-Badawi EA, Zawawi KH. Maxillomandibular Relationship in TMD Patients Before and After Short-Term Flat Plane Bite Plate Therapy. Cranio. 2003; 21(3):172-179.
22. Troeltzsch M, Troeltzsch M, Cronin RJ, Brodine AH, Frankenberger R, Messlinger K. Prevalence and association of headaches, temporomandibular joint disorders, and occlusal interferences. J Prosthet Dent. 2011; 105(6):410-417.
23. Hupfauf L, Weitkamp J. Ergebnisse der Behandlung von funktionsbedingten Erkrankungen des Kauorgans mit Aufbissbehelfen. Dtsch Zahnärztl Z. 1969; 24(5):347-352.
24. Lotzmann U. Okklusionsschienen und andere Aufbissbehelfe. München: Verlag Neuer Merkur; 1992.
25. Graber G. Orale Physiotherapie. Video-Anleitung zur Entspannung und Selbstmassage. Basel: Univ.-Zahnklinik; 1992.
26. Bernhardt O, Hawali S, Sümnick W, Meyer G. Electrical stimulation of the temporalis muscle during sleep of myofascial pain - a pilot study. J Cranio Mand Func. 2012; 4(3):197-210.



## Georg B. Meyer

DMD, PhD, Dr hc, Professor and Chairman  
Zentrums für Zahn-, Mund- und Kieferheilkunde  
Ernst-Moritz-Arndt Universität, Greifswald, Germany



## CV

Prof. Dr. Georg B. Meyer is the Head of Department Head for the Departments of Restorative Dentistry, Periodontology and Pedodontics at Ernst-Moritz-Arndt University of Greifswald / Germany and Head Instructor of Gnathology Department at the Academy of Practice and Science (APW) as well as President of the German Society of Dental, Oral and Cranium-mandible Sciences (DGZMK) and member of the Association of German Research Council (DFG). In 2006 he has received the title of "Professor Doctor Honoris Causa" awarded by the University of Dentistry - "Moscow State University". He has published several academics textbooks and many articles in international journals from over 30 countries.

## Questions

**Which of the following specialties is not involved in the multidisciplinary approach of the treatment of chronic headache:**

- a. neurology
- b. orthopedics
- c. psychology
- d. dentistry
- e. thoracic surgery

**Regarding masticatory functional disorders:**

- a. these are primarily caused by occlusal discrepancies
- b. premature occlusal contacts of less than 10 can lead to increased muscle activity, bruxism, sleep disorders, etc.
- c. Psycho-emotional stress does not influence masticatory functional disorders
- d. The occlusal disturbance represents the significant correlate for the neuromuscular dyscoordination or CMD from a scientific point of view

**Regarding the first patient:**

- a. Presented tension headaches only on the right half of the face
- b. Bilateral tinnitus was present
- c. No pain was present
- d. The patient had no history of orthodontic treatment

**Regarding the second patient:**

- a. The patient presented with constant pain
- b. The neurological examination was positive
- c. Mandibular movement was restricted
- d. The patient was completely dentate