

COMPLICATION RATE OF OSTEOCONDUCTIVE MEMBRANES OVER FRESH ALVEOLAR SOCKETS

Irina Pohodenko-Chudakova^{1a}, Tamara Tserkhava^{2b*}, Katsiaryna Maksimovich^{1c}, Yury Zenkevich^{2d}

¹Department of Oral Surgery, Dental Faculty, Belarusian State Medical University, Minsk, Republic of Belarus

²Department of Pediatric Dentistry, Dental Faculty, Belarusian State Medical University, Minsk, Republic of Belarus

^aMSD, PhD, Professor, Head

^bMSD, PhD, Professor, Head

^cDMD, Medical Science Doctoral Student, Assistant

^dDMD, Assistant

Received: July 16, 2017

Revised: July 29, 2017

Accepted: August 29, 2017

Published: August 30, 2017

Academic Editor: Gavriel Chaushu, DMD, MSc, Professor, Tel Aviv University, Tel Aviv, Israel

Cite this article:

Pohodenko-Chudakova I, Tserkhava T, Maksimovich K, Zenkevich Y. Complication rate of osteoconductive membranes over fresh alveolar sockets. *Stoma Edu J.* 2017;4(3):171-174.

ABSTRACT

DOI: 10.25241/stomaeduj.2017.4(3).art.2

Introduction: The aim of the study was to assess the clinical efficacy of the osteoconductive bioresorbable membranes "Collapan" and "Collost" used for the preservation of the alveolar process and to compare it with the natural bone healing of an alveolar socket.

Materials and methods: The 67 patients observed were divided into 3 groups. The first group included 20 individuals who were treated by covering the alveolus with the "Collapan" membrane. Group 2 included 22 patients in whom the "Collost" membrane was used. The third group (control) consisted of 25 patients in whom the alveolus was not covered with any membrane over the natural blood clot. The clinical efficacy of the membranes was based on the number of complications in the postoperative period. Also, the level of alveolar bone reduction was measured using residual height and width as parameters.

Results: In the postoperative period, 6 (9%) complications of an infectious-inflammatory nature were detected in group 1, 2 (3%) - in group 2, 19 (28%) - in group 3. The use of the "Collost" yielded the best result in preserving alveolar height and width.

Conclusion: The results of this pilot study showed that it is appropriate to use the osteoplastic bioresorbable "Collost" and "Collapan" membranes due to the low incidence of complications and the favourable effect on preserving bone volume.

Keywords: dentoalveolar surgery, alveolar socket preservation, osteoconductive membranes.

1. Introduction

Preservation of bone volume after tooth loss increases quality of life¹ and allows multiple choices of dental rehabilitation after tooth loss.²

Loss of alveolar bone volume after tooth extraction remains a challenge in oral surgery,³ both after tooth extraction and after loss of jaw bone due to tumor lesions in the jaw.⁴ The width of the alveolar ridge decreases in range from 25% to 50% during the first year, which is 5-7 mm, even in case of absence of complications after tooth extraction. It should be emphasized that 2/3 of the loss of the alveolar bone volume occurs during the first three months after tooth extraction. In the same period, there is a significant loss of bone volume in the vertical direction, which, as a rule, is 0.9-3.25 mm.³ Even removal of the third lower molar can lead to jaw bone loss,⁵ even in patients aged 15-35 years.⁶ Further, surgical manipulation and multiple curettage of alveolitis sicca could contribute to the

progression of alveolar bone atrophy. Bone loss at an age between 15-35 years also bears social and economic significance.^{7,8}

The aim of the study was to assess the clinical efficacy of the osteoconductive bioresorbable "Collapan" and "Collost" membranes used to minimize bone loss in the alveolar sockets in the lower jaw after tooth extraction and to compare it with the bone wound healing "under the blood clot".

There were 67 patients (men) under observation, aged 15 to 70 who were divided into 3 groups. All the patients signed the informed agreement for participation in the study, which was approved by the commission on bioethics of the Belarusian State Medical University.

The first group included 20 individuals in whom the "Collapan" membrane (Intermedapatit Ltd, Moscow, Russia) was used. Collapan is a biocomposite, consisting of synthetic hydroxyapatite, collagen and antimicrobial agent (lincomycin hydrochloride,

*Corresponding author:

Professor Tamara Tserkhava, MsD, PhD, Head of the Pediatric Dentistry Department, Dental Faculty, Belarusian State Medical University, 74-81, Dzerzhinski Ave., BY-220116 Minsk, Republic of Belarus
Tel: +375 17 272-61-96, Fax: +375 17 272-61-97, e-mail: tsetam@mail.ru

colloidal silver, gentamicin sulfate, metronidazole, claforan, rifampicin, dioxidine).

Group 2 included 22 patients in whom the “Collost” membrane (ZAO BioPHARMAHOLDING, Moscow, Russia) was used to cover the alveolar socket. Collost is a high-purity bovine collagen of type I under the form of a fully resorbable membrane. The third group consisted of 25 patients in whom the alveolar socket was not covered. Natural healing of the intra-alveolar blood clot was used to represent a normal control group.

Table 1 presents the three groups of patients (group 1 = collapse-group, group 2 = collost-group, group 3 = control) and the reasons for tooth extraction

(extraction group due to formation of apical cysts, extraction group due to chronic periodontitis, extraction group of third molars).

Grouping patients in the observation groups according to the volume of the bone lesion is presented in Table 2. According to the data presented in tables 1 and 2, it becomes obvious that the patient groups were comparable. There were no significant differences in the average age of each patient group. None of the participants in the study had any traumas, surgeries, somatic diseases requiring medical rehabilitation, maxillofacial and neck inflammation in the patient history, and were comparable according to the index of tooth decay,

Table 1. Grouping patients in the observation groups according to the diagnosis.

Diagnosis of the patients included in the observation group	Observation groups					
	Group 1, 30%, N=20		Group 2, 33%, n=22		Group 3, 37%, n=25	
Apical cyst (from one of the frontal teeth of the lower jaw)	5	7% 20%	6	9% 27%	7	11% 28%
Chronic periodontitis (molars and premolars of the lower jaw)	9	13% 45%	9	13% 41%	11	16% 44%
Dystopia, retention of third lower molars	6	9% 30%	7	11% 32%	7	11% 28%

Note: the upper value is calculated on the assumption that the total number of patients observed was taken as 100% (67), the lower value is calculated on condition that the number of patients in this group was taken as 100% of the total number of patients observed (20, 22, 25 respectively).

Table 2. Grouping patients in the observation groups according to the estimated volume of the bone lesion in the mandible.

Volume of the mandible bone lesion	Observation groups					
	Group 1, 30%, N=20		Group 2, 33%, n=22		Group 3, 37%, n=25	
Up to 1 cm	11	16% 55%	10	15% 45%	11	16% 44%
1 - 2 cm	8	12% 40%	10	15% 45%	13	19% 52%
More than 2 cm	1	2% 5%	2	3% 10%	1	2% 4%

Note: the upper value is calculated on the assumption that the total number of patients observed was taken as 100% (67), the lower value is calculated on condition that the number of patients in this group was taken as 100% of the total number of patients observed (20, 22, 25 respectively).

Table 3. Results of the study covering the height and width of the bone tissue (in mm) of the low jaw alveolar part in the groups of patients observed before the surgery and during the long-term observation period (after 1 year).

Studied parameters	Observation groups		
	Group 1 (n=20)	Group 2 (n=22)	Group 3 (n=25)
Height of the alveolar ridge	11.1 (9.7–20.4) $\sigma=\pm 2.0$	14.6 (11.2–22.3) $\sigma=\pm 2.2$	9.6 (7.1–17.9) $\sigma=\pm 2.4$
Width of the alveolar ridge	6.2 (4.2–9.0) $\sigma=\pm 0.7$	7.7 (5.1–10.2) $\sigma=\pm 0.9$	5.8 (4.0–9.2) $\sigma=\pm 0.8$

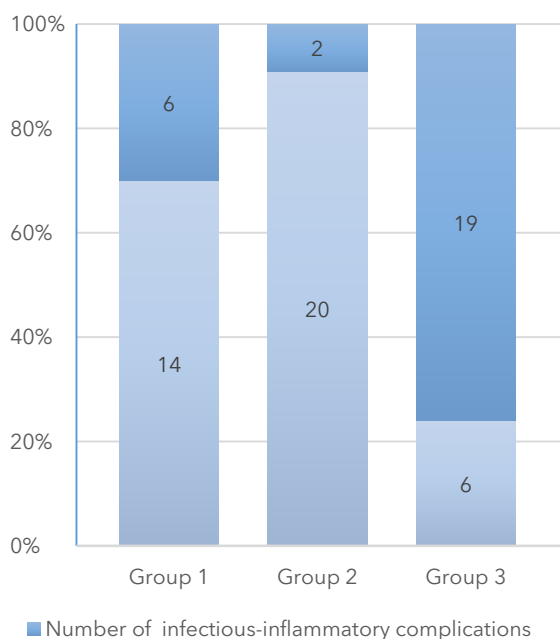


Figure 1. For each group the number of infectious-inflammatory complications is outlined together with the numbers of non-complicated cases in the same group.

seals, removed teeth and the level of hygiene of the oral cavity. The number of complications in the postoperative period was calculated.

The level of the alveolar bone loss was assessed during the long-term follow-up (after 1 year) on the basis of the mandibular bone tissue parameters determined on the basis of cone-beam computed tomography measurements also taken at 1 year postoperative. Measurements were carried out: 1) at two symmetrical points, in the area of chewing teeth, focusing on the location of the mandibular canal; 2) at two symmetrical points in the frontal part of the jaw, focusing on the line of canine teeth.⁹ The data obtained during the study were subjected to statistical processing using the "Statistica 10.0" software package.¹⁰

3. Results

In the postoperative period in group 1 there were 6 (9%) cases of infectious-inflammatory complications - alveolitis. Two (3%) of the cases occurred after the atypical removal of the third molar, and 4 (6%) after the operation of surgical tooth extraction.

In Group 2 there were 2 (3%) infectious-inflammatory complications: 1 (1.5%) case was alveolitis as a result

of the atypical removal of the third molar, 1 (1.5%) - tooth extraction that was performed 11 months after the previous operation of the root apex resection of 4.5 tooth and cystectomy. It should be mentioned that this latter complication can be attributed to the errors of endodontic preparation of the tooth for the operation, since according to the retrospective study of the primary documentation it is known that the root canal of 4.5 tooth was sealed more than 5 years ago and the clinical quality control of the canal filling was not carried out following the patient's insistence.

In Group 3, 19 (28%) infectious-inflammatory complications were detected. 7 (11%) complications occurred after the atypical removal of the third molar, 9 (13%) after the surgical extractions of the lower jaw molars / premolars following a diagnosis of chronic granulomatous periodontitis, in 3 (4%) cases the chronic granulomatous periodontitis was without exacerbation. The results obtained are consistent with the reports in scientific literature.¹²

The complication ratio in the different groups is shown in Figure 1. The results of the volume measurements indicate a preservation of bone volume, which is highest in the "Collost" group, followed by the "Collapan" group and the controls (Table 3).

4. Discussion

The present study highlights the advantage of using the osteoconductive bioresorbable "Collost" membrane for the prevention of the mandible alveolar socket atrophy, which is in line with the reports of Seliverstov et al. and Medvedev et al. (2015).^{13,14}

5. Conclusion

The results of the study showed that the use of osteoconductive bioresorbable "Collost" and "Collapan" membranes does not increase the complication rate of alveolar socket healing in the mandible. These preliminary results favour "Collost" over "Collapan".

Author Contributions

Equal contribution to the paper.

Acknowledgments

The authors declare no conflict of interest related to this study. There are no conflicts of interest and no financial interests to be disclosed.

References

1. Tarn DM, Paterniti DA, Good JS, et al. Physician-patient communication about dietary supplements. *Patient Educ Couns.* 2013;91(3):287-294. doi: 10.1016/j.pec.2013.01.021. [Full text links] [Free PMC Article] [PubMed]
2. Odin G, Misch CE, Binderman I, Scortecchi G. Fixed rehabilitation of severely atrophic jaws using immediately loaded basal disk implants after in situ bone activation. *J Oral Implantol.* 2012;38(5):611-616. doi: 10.1563/AAID-JOI-D-10-00163. [Full text links] [PubMed]
3. Andreasi Bassi M, Andrisani C, Lopez MA, et al. Guided bone regeneration by means of a preformed titanium foil: a case of severe atrophy of edentulous posterior mandible. *J Biol Regul Homeost Agents.* 2016;30(2 Suppl 1):35-41. [PubMed]
4. Krasilnikov AA, Nikolaev CM, Markarjan AA, et al. [Influence of "Collost" and "Collost with chymotrypsin" for bone defect healing]. *DSPU. J Natural and Exact Sciences. (Rus.).* 2011;4:75-79.
5. Fickl S, Fischer K, Petersen N, et al. Dimensional evaluation of different ridge preservation techniques: a randomized clinical study. *Int J Periodontics Restorative Dent.* 2017;37(3):403-410. doi: 10.11607/prd.2629. [PubMed]
6. Prajapati VK, Mitra R, Vinayak KM. Pattern of mandibular

- third molar impaction and its association to caries in mandibular second molar: a clinical variant. Dent Res J (Isfahan). 2017;14(2):137-142. [[Free PMC Article](#)] [[PubMed](#)]
7. Kuehn DP. Orofacial embryology, anatomy and physiology. Ann Otol Rhinol Laryngol Suppl. 1980;89(5 Pt 2):138-141. [[PubMed](#)]
 8. Cotofana S, Fratila AA, Schenck TL, et al. The anatomy of the aging face: a review. Facial Plast Surg. 2016;32(3):253-260. doi: 10.1055/s-0036-1582234. [[Full text links](#)] [[PubMed](#)]
 9. Lazarenko AV, Kan VV, Terskikh SA. [Jaw bone measurement evaluation in fully and partially edentulous patients of retirement age]. Kuban Nauch Med Vestn. (Rus.). 2015;2(151):93-97.
 10. Everitt BS. Medical statistics from A to Z. A guide for clinicians and medical students, 2nd Edition. Cambridge, 2007. Available from: <http://rutracker.org/forum/viewtopic.php?t=1777615>. [Accessed 4th July 2017].
 11. Grakovich AA, Brovko IV, Reutskaya LA, et al. [Procedure for conducting clinical and economic research: instruction for use № 075-0708: approved]. Health Ministry Rep. Belarus 03.10.08. Minsk; 2008; 13-16.
 12. Ricard AS, Nau O, Veyret A, et al. [Comparison between closure and absence of closure after removal of fully impacted mandibular third molar: a prospective randomized study]. Rev Stomatol Chir Maxillofac Chir Orale. 2015;116(1):12-7. doi: 10.1016/j.revsto.2014.11.009. [[Full text links](#)] [[PubMed](#)]
 13. Medvedev YuA, Dyachkova EYu. [The surgical treatment of patients with jaw defects after removing teeth based on the utilization of osteoplastic material "Collost"]. Int Rev Clin Practice and Health. (Rus.). 2015;6:38-45.
 14. Seliverstov DV, Kuznecov AV, Masevnin VV, et al. [Application of the "Collost" biomaterial in the complex surgical treatment of pressure ulcers of the IV degree]. Rus Med J. (Rus.). 2015;13:776-780.

Irina POHODENKO-CHUDAKOVA

MSD, PhD, Professor, Head of the Department of Oral Surgery, Belarusian State Medical University Minsk, Republic of Belarus



CV

Irina Pohodenko - Chudakova was born on 2.02.1968. In 1990 she graduated from the Dental Faculty of the Minsk State Medical Institute (nowadays Belarusian State Medical University). Irina Pohodenko - Chudakova is a Doctor of Medical Science, Professor, Head of the Department of Surgical Dentistry of the Belarusian State Medical University. She authored more than 730 scientific works (including 7 monographs, 17 patents, 30 rationalization proposals and 43 educational-methodological works).

Under her guidance, 6 doctoral theses are currently being defended. Irina Pohodenko - Chudakova has been the recipient of honorary diplomas awarded by the Ministry of Health of the Republic of Belarus, the Ministry of Education of the Republic of Belarus, and the Rector of the Belarusian State Medical University.

Questions

Prevention of atrophy of the alveolar part of the lower jaw is performed by:

- a. Otorhinolaryngologist;
- b. Ophthalmologist;
- c. Maxillofacial surgeon;
- d. Traumatologist.

Which disease below is considered as organ-saving?

- a. Tooth extraction;
- b. Resection of the apex of the tooth root;
- c. Periosteotomy;
- d. Dental implantation.

Please, choose the indices used in medicine:

- a. Leukocyte index of intoxication (LII);
- b. Iatrogenic indices (JI);
- c. Simplified index of oral hygiene (OHI-S);
- d. Blood leukocyte shift indexes (BLSI).

Please, choose the osteoplastic medicine:

- a. "Collost";
- b. Anticain;
- c. Acetylsalicylic acid;
- d. Chlorhexidine bigluconate.