

## A RADIOGRAPHIC STUDY TO DETERMINE THE POSSIBLE EXISTENCE OF A "SAFE ZONE" AGAINST ENDODONTIC PERIAPICAL EXTRUSION IN THE LOWER PREMOLAR

Wei Cheong Ngeow<sup>1a\*</sup>, Dionetta Delitta Dionyssius<sup>1b</sup>, Hayati Ishak<sup>1b</sup>

<sup>1</sup>Department of Oro-Maxillofacial Surgical and Medical Sciences, Faculty of Dentistry, University of Malaya, Kuala Lumpur, Malaysia

<sup>a</sup>BDS (Mal), FFDRCS (Ire), FDSRCS (Eng), MDSc (Mal), PhD (Sheffield), FAMM

<sup>b</sup>BDS (Mal)

Received: March 09, 2016

Revised: May 30, 2016

Accepted: June 29, 2016

Published: July 01, 2016

Academic Editor: Paula Perlea, DMD, PhD, Associate Professor, Dean, "Carol Davila" University of Medicine and Pharmacy Bucharest, Bucharest, Romania

### Cite this article:

Ngeow WC, Dionyssius DD, Ishak H. A radiographic study to determine the possible existence of a "safe zone" against endodontic periapical extrusion in the lower premolar. *Stoma Edu J.* 2017;4(2):108-113.

### ABSTRACT

DOI: 10.25241/stomaeduj.2017.4(2).art.3

**Introduction:** Studies have shown that the most common position of the mental foramen in several Asian populations was in line with the apex of the second premolar. Therefore, we seek to determine the average distance of the mental foramen to the apex of the second premolar by using the crown length of the second premolar as a ruler. We hope to define a "safe zone" in this region.

**Methodology:** Measurements were made from the apex of the second premolar to the mental foramen of ninety seven dental radiographs fulfilling the criteria set.

**Results:** Non-detection of mental foramina happened significantly more often in female subjects than male (Pearson Chi-square;  $p=0.01$ ). Of the mental foramina that were visible, 96% were found to be located within one-crown distance from the apex. More mental foramina (37.1%; 56 sites) were located at the apex than any other locations. This is followed by finding the mental foramina located at ¼-crown distance from the apex (26.5%; 40 sites). The visibility of the mental foramen was found to be significantly limited in females and in patients aged 50 and above (Pearson Chi-square;  $p<0.05$ ).

**Conclusion:** These findings suggest that there is no safe zone against accidental extrusion of endodontic files and materials in the second premolar region.

**Keywords:** endodontology, complication, inferior alveolar nerve, mental nerve, mental foramen.

### 1. Introduction

The mental foramen is located close to the mandibular premolars, especially the second premolar.<sup>1</sup> A morphometric study by Philips et al.<sup>2</sup> reported the mental foramen to be located on average at a distance of 2.18 mm mesially and 2.4 mm inferiorly from the plain radiographic apex of the second premolar. More precisely, the mental foramina could be located anywhere 3.8 mm mesially 2.7 mm distally, 3.4 mm above or 3.5 mm below the apex of the second premolar. Various cadaveric studies reported the apices of the second premolars to be between 0 and 4.7 mm away from the mental foramen.<sup>3,4</sup> Using a newer technology of cone beam computed tomography (CBCT), Bürklein et al.<sup>5</sup> also reported similar findings, with an average distance of 4.2 mm. However, 3.2% of the mental foramen was directly in contact with the second premolar.

Because of this close proximity, various events affecting the second premolar, such as odontogenic infection and orthodontic, endodontic, periodontal or surgical misadventure, may result in the neurosensory disturbance to the area innervated by the mental nerve that exits the mental foramen.<sup>1,6</sup> A retrospective study found an incidence of 0.96% of

mental paraesthesia related to root canal treatment of mandibular premolar teeth. However, all these incidents were related to periapical infection or pathology, instead of being a complication of the root canal treatment itself as the authors excluded 2 (0.24%) cases of severe overfill and iatrogenic root perforation with mechanical instrumentation into the mental nerve.<sup>3</sup>

Eliminating infection in the pulp and dentin, followed by adequate intra-canal preparation and proper sealing constitute the basic principles of root canal treatment. Ideally, mechanical preparation and filling should be limited within the root canal as overinstrumentation or the extrusion of chemical fillings beyond the apical foramen to the adjacent nerve can give rise to NSD such as paraesthesia or anaesthesia.<sup>7,8</sup> Paresthesia related to overinstrumentation usually resolves within several days.<sup>9</sup> In addition, minor material extrusions are generally well tolerated by the periradicular tissues as long as they do not spread to the adjacent nerve.<sup>10</sup> However, long-term NSD has been reported in cases where the nerve fibre is lacerated due to overinstrumentation or in contact with toxic overfilled endodontic materials.<sup>8,11</sup>

### \*Corresponding author:

Professor Dr Wei Cheong Ngeow, Department of Oral & Maxillofacial Clinical Sciences, Faculty of Dentistry, University of Malaya, 50603 Kuala Lumpur, Malaysia  
Tel: 603-79674862, Fax: 603-79674534, e-mail: ngeow@um.edu.my

As the close proximity of the apices of the mandibular premolar to the mental foramen acts as an important contributory factor for NSD when overinstrumentation or overfilling of endodontic materials happen, it is the aim of this study to determine the distance of the mental foramen to the second mandibular premolar tooth. We chose to concentrate on the second premolar only as an earlier study has shown that most of the terminal end of the inferior alveolar nerve is located in line with the apex of the second premolar.<sup>12</sup> In this pilot study, also conducted on a selected Malay population, we seek to determine the average distance of the mental foramen from the apex of the second premolar by using the crown height of the second premolar as a ruler. The identification of this distance, will hopefully enable us to come up with a so called "safe zone" to ensure that root canal treatment in the lower premolar region can be performed with minimum complications in case files or endodontic filling materials are accidentally extruded beyond the apices of these premolars.

## 2. Methodology

### 2.1. Materials

One hundred twenty panoramic radiographs of Malay patients of 4 different age-groups, taken between 2003 and 2005 were obtained from the records stored by the Dental Faculty of the University of Malaya, Kuala Lumpur, Malaysia. The age-groups were categorised as 20-29 years-old, 30-39 years-old, 40-49 years-old and 50 years and above.

All panoramic radiographs were taken using Siemen Orthophos® (Sirona, Bensheim, Germany) or Planmeca® (Planmeca, Helsinki, Germany) machines. The magnification factors reported by the manufacturers were 1.2 and 1.25, respectively. The radiographs were chosen according to the following criteria:

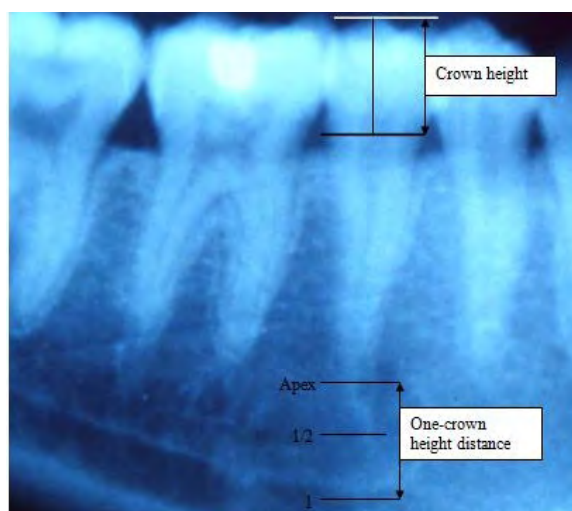
1. High quality with respect to geometric accuracy and contrast of the image.
2. Radiographs in which the lower teeth (between 36 and 46) were missing, had deep caries, root canal treatment or various restorations were excluded because of possible associated periapical radiolucency.
3. Radiographs must be free from any radiolucent or radiopaque lesion in the lower arch. There should be no evidence of jaw fracture around the mental foramen region.
4. Radiographs with supernumeraries and unerupted teeth were excluded because the impacted/ unerupted teeth might obscure the appearance of mental foramen.
5. Films should be devoid of any radiographic exposure or processing artefacts.
6. Radiographs where the lower canine was missing were excluded because of the possibility of mesial premolar drift.
7. Radiographs in which the upper premolars were missing were excluded because of the possibility of overeruption of the lower premolars.

### 2.2. Methods

The dental panoramic radiographs were placed on

a radiograph view-box. A transparent tracing paper was placed over the radiograph and fixed properly to ensure it remain static in relation to the film. An imaginary line was drawn to outline the second premolar. A line was drawn to join the mesial and distal points of the cement-enamel junction (CEJ). Another line was drawn at the tip of the crown, parallel to the line joining the CEJs. A line vertical to both these lines was then drawn. It represents the crown height of the second premolar. A pair of caliper was used to transfer this distance to a metal ruler to obtain an exact measurement. This measurement was then divided by 4 (calculated to the nearest millimeter) to give the height of a quarter-crown. The distance from the mental foramen to the apex was measured using the second premolar crown height as a ruler (Fig. 1) and was categorised as below:

- I. located at apex
- II. within ¼-crown-distance
- III. within ½-crown-distance
- IV. within ¾-crown-distance
- V. within 1-crown-distance
- VI. within 1½-crown-distance
- VII. within 2-crown-distance
- VIII. Could not be identified



**Figure 1.** An illustration showing the method used to determine the distance of the mental foramen to the apex of the second premolar using the crown height as a ruler (Note: In this dental panoramic radiograph, the mental foramen is located at the apex of the second premolar).

## 3. Results

There were a total of 97 radiographs with bilateral sites that fulfilled the criteria and were examined. Thirty-one of the subjects fell into those aged between 20-29 years, 24 subjects were between 30-39 years old, 22 between 40-49 years old and the final 20 were aged 50 years and above. The number of subjects (hence radiographs) that fulfilled the criteria set became less with the age increase as there was a high number of subjects who become fully edentulous or partially edentulous beginning from the first premolar.

The mental foramen was visible in 77.8% (151) of the sites reviewed. It was slightly more pronounced on

**Table 1.** Distribution for location of mental foramina according to age-groups.

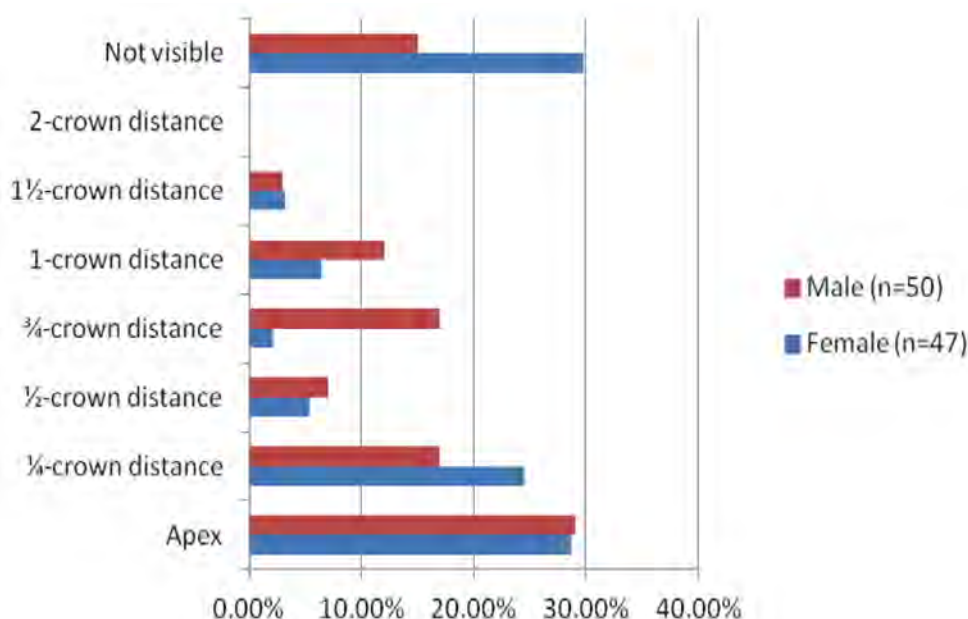
Location	20-29 years [site/percentage]	30-39 years [site/percentage]	40-49 years [site/percentage]	≥ 50 years [site/percentage]
<b>Apex</b>	23 (37.1%)	17 (35.4%)	9 (20.4%)	7 (17.5%)
<b>¼-crown</b>	14 (22.6%)	11 (22.9%)	11 (25%)	4 (10%)
<b>½-crown</b>	4 (6.4%)	5 (10.4%)	3 (6.8%)	0 (0%)
<b>¾-crown</b>	4 (6.4%)	2 (4.2%)	11 (25%)	2 (5%)
<b>1-crown</b>	6 (9.7%)	7 (14.6%)	2 (4.5%)	3 (7.5%)
<b>1½-crown</b>	0 (0%)	2 (4.2%)	1 (2.3%)	3 (7.5%)
<b>2-crown</b>	0 (0%)	0 (0%)	0 (0%)	0 (0%)
<b>Not visible</b>	11 (17.8%)	4(8.3%)	7 (16.0%)	21 (52.5%)

the left (80.5%; 78 sites) than the right side (75.3%; 73 sites) of the mandible. Out of the mental foramina that were visible, 96% were found to be located within a one-crown distance from the apex. More mental foramina (37.1%; 56 sites) were located at the apex than at any other locations. This is followed by finding the mental foramina located within a ¼-crown distance from the apex (26.5%; 40 sites).

Table 1 shows the overall distribution of mental foramen according to various age groups. The mental foramina were visible in the majority of panoramic radiographs of subjects under the age of 50 years (20-29 years: 82.3%; 30-39 years: 91.7%; 40-49 years: 84.1%). However, they did not become visible in more than half (52.5%) of panoramic radiographs of subjects aged 50 and above. This finding is statistically significant (Pearson Chi-square;  $p < 0.001$ )

Age-wise, all mental foramina were noted to be located within a one-crown distance from the apex in panoramic radiographs of subjects aged 20-29 years. However, between 84.2% and 95.4% of them were located within a one-crown distance for the remaining 3 age groups.

Figure 2 shows the distribution of the mental foramina according to the gender of the subjects. The majority of the foramina were located within a one-crown distance from the apex, irrespective of gender (female 95.4%; male 96.5%). The apex of the second premolar was the most common location for finding mental foramen in both genders (female 40.9%; male 34.1%). However, there were gender differences for other locations, with the ¼-crown distance being the second most common for female but ¼- and ¾-crown distance for the male. When the mental foramina were not observed, more of



**Figure 2.** Distribution of the mental foramina according to the gender of the subjects.

this happened in panoramic radiographs of female subjects (28 sites) than male (15 sites). This difference was statistically significant (Pearson Chi-square;  $p=0.01$ )

#### 4. Discussion

Neurosensory disturbance (NSD) after root canal treatment is an outcome of a rare accident at the apical region of the mandibular posterior teeth. Numerous reports have been published describing the occurrence of NSD during and after endodontic treatment of the mandibular premolars<sup>7,8,13,14</sup> with the possible mechanisms attributed to 3 factors, namely mechanical, chemical, and thermal damage. Mechanical damage results from compression that occurs during overinstrumentation or by the filling material forced into the mandibular canal.<sup>15</sup> Chemical damage, on the other hand, happens where there is an extrusion of cytotoxic products used during root canal preparation (irrigation and/or root canal medication) or obturation while thermal damage is related to a lack of control in thermocompaction filling techniques.<sup>9,16</sup>

The close proximity of the apices of the mandibular premolar and molar teeth to the mental foramen and mandibular canal facilitate NSD to happen when overinstrumentation or overfilling of endodontic materials happened.<sup>1,15</sup> In the molar/premolar region, the inferior alveolar nerve describes a curve that brings the second premolar as well as the second molar root apices in closest proximity to the nerve.<sup>4</sup> Not many researchers have looked into the distance of the premolar teeth to the terminal end of the inferior alveolar nerve, namely the mental nerve and its foramen.<sup>2,3,4,5</sup> Worse all of these studies were undertaken on Caucasian subjects. We, therefore, feel it is timely to study this relationship in Asia due to the fact that endodontic extrusions with complication are still being reported every now and then. We hoped to define a "safe zone" apical to the mandibular second premolar, if one indeed exists.

Bürklein et al.<sup>5</sup> recently undertook such a study using data generated from cone beam computed tomography. However, CBCT is not as widely used in our centre, and we instead have a huge archive of data stored in panoramic radiographs. Hence we decided to study the premolar-mental foramen relationship in panoramic radiographs as this is still relevant clinically. However, as measurement done on panoramic radiographs is generally considered distorted, it was decided that the crown height was used as a comparative ruler because of two reasons: a) the inability to accurately measure the length/distance as these images were in hard copies, as opposed to the newer machine with a measuring software, and

b) for clinical application sake, whereby it was felt that dentists/endodontists may want to have a mental map of the "safe zone" around the premolar region, which can easily be related to the crown-height of the tooth concerned. This may become important when only a periapical radiograph is taken for endodontic purpose.

It is well accepted that dental panoramic radiographs have some disadvantages, namely, variable

magnification from 10% to 30%, image distortion and invisibility in the facio-lingual dimension. Therefore, measuring directly on different radiographs taken using different machines with different distortion would result in a compromised finding. However, by calculating a ratio based on the crown height as a tool of measurement, it is hoped that this will ensure that we are always consistent in relating distance between the mental foramen and the apex of the second premolar. This ratio can be used to provide a mental picture of the distance available based on the average crown height of a mandibular second premolar of 8.2 mm, with a crown to root ratio of 1:1.8.<sup>17</sup>

Translating the finding that 96% of mental foramina were found to be located within one-crown distance from the apex, this can easily suggest that a majority of the mental foramina were located within a 8.2 mm perimeter from the apices of the second premolar. Worse, almost two-thirds (63.6%) of the mental foramina were located either at the apex or within a quarter crown-height distance from the apex, translating to a 'safe zone' between 0 to 2 mm only! Nevertheless, the distance recorded in this study is still larger than that reported by Phillips et al.<sup>2</sup> where the centre of the mental foramen was located on an average distance of 2.18 mm mesially and 2.4 mm inferiorly from the radiographic apex of the second premolar. Our finding, together with that reported by Phillips et al.<sup>2</sup> earlier, suggests that there is no really "safe zone" against accidental extrusion of endodontic files and materials in the second premolar region.

Two secondary findings that are statistically significant are the fact that more mental foramina were not noticeable in female patients and in patients aged more than 50 years old. The latter finding has been reported in an earlier publication.<sup>18</sup> The effect of gender on non-visibility of mental foramen has not been reported, and could be related to the difficulty to distinguish it from trabeculae pattern in these patients, in addition to poor radiograph quality (over dark radiographs).<sup>19</sup> As osteoporosis affects female subjects more than males, it is possible that is a potential contributing factor although this suggestion remains a hypothesis due to the fact that we did not actively seek to determine if these subjects were indeed having bone metabolism disorder.

#### 5. Conclusion

More mental foramina were significantly not visible in panoramic radiographs of female subjects than male. Of mental foramina that were visible, 96% were found to be located within one-crown distance from the apex. Almost two-thirds (63.6%) of the mental foramina were located either at the apex or within a quarter crown-height distance from the apex. The visibility of the mental foramen was found to be significantly limited in patients aged 50 and above. These findings suggest that there is no "safe zone" for accidental extrusion of endodontic files and materials in the second premolar region.

#### Acknowledgments

The authors report no conflict of interest and there was no external source of funding for the present study.

## References

1. Ngeow WC. Is there a "safety zone" in the mandibular premolar region where damage to the mental nerve can be avoided if periapical extrusion occurs? *J Can Dent Assoc.* 2010;76:a61. [Full text links] [Free Article] [PubMed] Google Scholar(11) Scopus(6)
2. Phillips JL, Weller RN, Kulild JC. The mental foramen: 2. Radiographic position in relation to the mandibular second premolar. *J Endod.* 1992;18(6):271-274. [PubMed] Google Scholar(85)
3. Knowles KI, Jergenson MA, Howard JH. Paresthesia associated with endodontic treatment of mandibular premolars. *J Endod.* 2003;29(11):768-770. doi:10.1097/00004770-200311000-00019 [Full text links] [PubMed] Google Scholar(55) Scopus(30)
4. Denio D, Torabinejad M, Bakland LK. Anatomical relationship of the mandibular canal to its surrounding structures in mature mandibles. *J Endod.* 1992;18(4):161-165. doi: 10.1016/S0099-2399(06)81411-1 [Full text links] [PubMed] Google Scholar(117) Scopus(52)
5. Bürklein S, Grund C, Schäfer E. Relationship between root apices and the mandibular canal: a cone-beam computed tomographic analysis in a German population. *J Endod.* 2015;41(10):1696-1700. doi: 10.1016/j.joen.2015.06.016 [Full text links] [PubMed] Google Scholar(12) Scopus(7)
6. Ngeow WC. Lower lip numbness due to peri-radicular dental infection. *Med J Malaysia.* 1998; 53(4): 446-448. [Full text links] [Free article] [PubMed] Google Scholar(9) Scopus(4)
7. Poveda R, Bagan JV, Fernandez JM, et al. Mental nerve paresthesia associated with endodontic paste within the mandibular canal: report of a case. *Oral Surg Oral Med Oral Pathol Oral Radiol Endod.* 2006;102(5):e46-49. doi: 10.1016/j.tripleo.2006.03.022 [Full text links] [PubMed] Google Scholar(75) Scopus(31)
8. Pogrel MA. Damage to the inferior alveolar nerve as the result of root canal therapy. *J Am Dent Assoc.* 2007;138(1):65-69. [Full text links] [PubMed] Google Scholar(134) Scopus(73)
9. Di Lenarda R, Cadenaro M, Stacchi C. Paresthesia of the mental nerve induced by periapical infection: a case report. *Oral Surg Oral Med Oral Pathol Oral Radiol Endod.* 2000;90(6):746-749. [Full text links] [PubMed] Google Scholar(50) Scopus(29)
10. Pertot WJ, Camps J, Remusat M, Proust JP. In vivo comparison of the biocompatibility of two root canal sealers implanted into the mandibular bone of rabbits. *Oral Surg Oral Med Oral Pathol.* 1992;73(5):613-620. [PubMed] Google Scholar(52) Scopus(17)
11. Morse DR. Endodontic-related inferior alveolar nerve and mental foramen paresthesia. *Compend Contin Educ Dent* 1997;18(10):963-968, 970-973, 976-978 passim; quiz 998. Review. [PubMed] Google Scholar(60) Scopus(33)
12. Ngeow WC, Yuzawati Y. The location of the mental foramen in a selected Malay population. *J Oral Sci.* 2003;45(3):171-175. [PubMed] Google Scholar(151) Scopus(73)
13. Scarano A, Di Carlo F, Quaranta A, et al. Injury of the inferior alveolar nerve after overfilling of the root canal with endodontic cement: a case report. *Oral Surg Oral Med Oral Pathol Oral Radiol Endod.* 2007;104(1):e56-59. doi: 10.1016/j.tripleo.2007.01.036 [Full text links] [PubMed] Google Scholar(42) Scopus(14)
14. Grötz KA, Al-Nawas B, de Aguiar EG, et al. Treatment of injuries to the inferior alveolar nerve after endodontic procedures. *Clin Oral Investig.* 1998;2(2):73-76. [PubMed] Google Scholar(62) Scopus(38)
15. Scolozzi P, Lombardi T, Jaques B. Successful inferior alveolar nerve decompression for dysesthesia following endodontic treatment: report of 4 cases treated by mandibular sagittal osteotomy. *Oral Surg Oral Med Oral Pathol Oral Radiol Endod.* 2004;97(5):625-631. doi: 10.1016/S1079210404000502 [Full text links] [PubMed] Google Scholar (93) Scopus(49)
16. Tilotta-Yasukawa F, Millot S, El Haddioui A, et al. Labiomandibular paresthesia caused by endodontic treatment: an anatomic and clinical study. *Oral Surg Oral Med Oral Pathol Oral Radiol Endod.* 2006;102(4):e47-59. doi: 10.1016/j.tripleo.2006.02.017 [Full text links] [PubMed] Google Scholar(67) Scopus(30)
17. Scheid RC, Weiss G. Woelfel's Dental anatomy: Its relevance to Dentistry. 8th ed. Chapter 3: Basis terminology for understanding tooth morphology. Philadelphia, PA: Lippincott Williams & Wilkins; 2012. Google Scholar(90)
18. Ngeow WC, Dionysius DD, Ishak H, et al. Effect of ageing towards location and visibility of mental foramen on panoramic radiographs. *Singapore Dent J.* 2010;31(1):15-19. doi: 10.1016/S0377-5291(12)70004-4 [Full text links] [Free article] [PubMed] Google Scholar(8) Scopus(7)
19. Yosue T, Brooks SL. The appearance of mental foramina on panoramic and periapical radiographs. II. Experimental evaluation. *Oral Surg Oral Med Oral Pathol.* 1989;68(4):488-492. [PubMed] Google Scholar(76) Scopus(33)

### Wei Cheong NGEOW

BDS (Mal), FFDRCS (Ire), FDSRCS (Eng), MDS (Mal)  
PhD (Sheffield), FAMM, Professor Dr  
Department of Oral & Maxillofacial Clinical Sciences  
Faculty of Dentistry, University of Malaya  
Kuala Lumpur, Malaya



## CV

Professor Dr Wei Cheong Ngeow graduated from the Faculty of Dentistry of the University of Malaya in 1992 and went into private practice before being offered a tutorship at his alma matter. In 1996, he obtained his Fellowship in Dental Surgery from the Royal Colleges of Surgeons in Ireland and England, respectively. Back in Malaysia he was a pioneer lecturer at the newly established Universiti Kebangsaan Malaysia. He returned to private practice in 1999 but in 2000 returned to the University of Malaya He obtained an MDS (2008) and a PhD from the University of Sheffield (2010). He has published over 160 articles, letters, comments and reports in local and international journals, and was the Editor of the Malaysian Dental Journal (2005-2007) and Editor of the MDA Newsletter (2015). His research interests are craniofacial anthropometry, variations of the mandibular nerve, recovery of peripheral nerves after microsurgical repair.

## Questions

### 1. Which tooth is usually closely related to the mental foramen?

- a. First premolar;
- b. Second premolar;
- c. First molar;
- d. Second molar.

### 2. Which of the following statements is not the main principle of endodontic treatment?

- a. Eliminating pain;
- b. Eliminating infection in pulp and dentine;
- c. Achieving adequate intracanal preparation;
- d. Achieving proper seal.

### 3. The following is not a factor that contributes to the occurrence of neurosensory disturbance during endodontic treatment of the mandibular premolars:

- a. Mechanical;
- b. Chemical;
- c. Thermal;
- d. Psychological.

### 4. When translating the finding that 96% of mental foramina were found to be located within one-crown distance from the apex, how far are the majority of the mental foramina located within from the apices of the second premolar?

- a. 6 mm;
- b. 7 mm;
- c. 8 mm;
- d. 9 mm.

28<sup>th</sup> Asia Pacific Congress on  
**Dental and Oral Health**  
July 10-12, 2017  
**KUALA LUMPUR**  
Everything you need to know

<http://www.dentalcongress.com/asia-pacific/>  
Email:  
[dentalcongress@dentistryconferences.com](mailto:dentalcongress@dentistryconferences.com)  
[dentalcongress@conferenceseries.net](mailto:dentalcongress@conferenceseries.net)

**ADA C.E.R.P.**<sup>®</sup>  
Continuing Education Recognition Program