

## Cite this article:

Showkatbakhsh R, Jamilian A, Alipanahi M, Perillo L. Treatment Effects of R-Appliance in Vertical Growing Patients-Case Series. *Stoma Edu J.* 2014;1(2): 102-107.

# TREATMENT EFFECTS OF R-APPLIANCE IN VERTICAL GROWING PATIENTS-CASE SERIES

[https://doi.org/10.25241/stomaeduj.2014.1\(2\).art.4](https://doi.org/10.25241/stomaeduj.2014.1(2).art.4)

**Rahman Showkatbakhsh<sup>1a</sup>,  
Abdolreza Jamilian<sup>2a\*</sup>,  
Minoo Alipanahi<sup>2b</sup>,  
Letizia Perillo<sup>3c</sup>**

1. Department of Orthodontics, Shahid Beheshti University of Medical Sciences, Tehran, Iran

2. Department of Orthodontics, Tehran Dental Branch, Craniomaxillofacial Center Islamic Azad University, Tehran, Iran

3. Departments of Orthodontics, Second University of Naples, Naples, Italy

a. DDS, PhD, Associate Professor

b. DDS

c. DDS, PhD, Professor

## Abstract

The purpose of this study was to evaluate the effects of a functional appliance (the R-appliance) on Class II division I vertical growth pattern patients with mandibular deficiency. Twenty patients (13 girls and 7 boys) of an average age of 10.6 (SD 0.8) years were treated with R-appliance for 16 (SD 0.4) months. All patients had Class II division 1 malocclusions due to mandibular deficiency and were vertical growers. Lateral cephalograms obtained at the beginning (T1) and at the end (T2) of the study were analyzed. Paired t-tests showed that SNB significantly increased from 72.8° (SD 2.2°) to 76° (SD 1.8°) ( $P < 0.001$ ) after treatment. The incisor mandibular plane angle (IMPA) significantly decreased and the Jarabak index increased for 1.7% (SD 2.5%) ( $P < 0.007$ ). R-appliance was successful in moving the mandible forward in vertical growth pattern patients without proclination of the lower incisors.

**Keywords:** Functional Appliance, Class II Division 1, mandibular deficiency, R-appliance, vertical growth pattern

## Introduction

Class II division 1 malocclusion due to mandibular deficiency is a commonly observed clinical problem (1, 2), and it has been extensively studied for skeletal and dental characteristics (3, 4). Different functional appliances have been used to treat this malocclusion (5-13). Functional appliances put the mandible in forward position, result in stretches on the related attached muscular groups of the mandible, and create bone remodeling and muscular adaptation (14-21). However, it is reported in the literature that functional appliances can cause restriction of maxillary growth (5, 22, 23). Moreover, flaring of lower incisors is another of their disadvantages (24, 25). The influence of functional appliances in the vertical relation of the bone bases is a controversial subject in literature. Most of the time, functional appliances are not recommended in vertical growth pattern patients because these appliances can cause a subsequent clockwise mandibular rotation and, consequently, may worsen the facial esthetics (18, 26).

Restriction of the maxilla, proclination of lower anteriors and being unsuitable in treatment of vertical growers are the main disadvantages of traditional functional appliances. In order to overcome these disadvantages and correct vertical growth pattern patients, R-Appliance was designed.

## Methods and Materials:

Written consent was obtained from each patient or parent according to the ethical principles of the Declaration of Helsinki and was approved by IAU Local Research Ethics Committees.

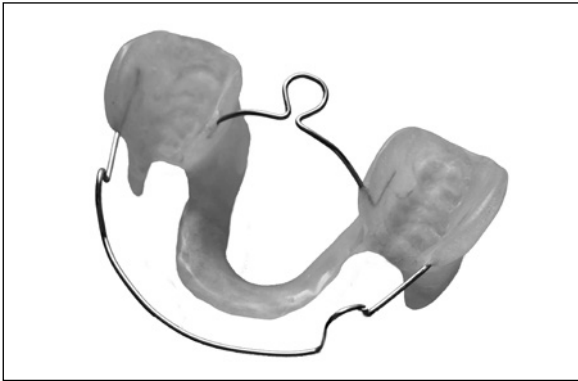
The study consisted of 23 consecutive patients with skeletal Class II division I malocclusion, mandibular deficiency and vertical growth pattern. Three of the patients dropped out because they could not meet the appointments due to personal reasons. The remaining 20 samples were 7 males and 13 females with the mean age of 10.6 (SD 0.8) years. All subjects met the following inclusion criteria:

Received: 20 August 2014  
Accepted: 29 October 2014

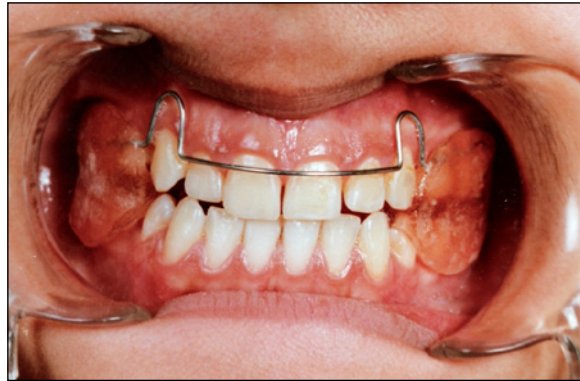### \* Corresponding author:

Associate Professor Abdolreza Jamilian,  
DDS, PhD

Department of Orthodontics, Tehran Dental Branch, Islamic Azad University  
2713, Vali Asr St., Tehran 1966843133, Iran  
Tel: 0098-21-22011892  
Fax: 0098-21-22022215  
e-mail: info@jamilian.net



**Figure 1.** The R-appliance



**Figure 2.** The R-appliance in the mouth

1. ANB > 4°, SNB < 78°, overjet > 4 mm at the initial lateral cephalograms;
2. Nonsyndromic or medically compromised patients;
3. No previous surgical intervention;
4. No use of other appliances before or during the period of functional treatment.
5. No skeletal asymmetry
6. Vertical growth pattern (GoGn-SN > 32°)

All the patients were treated with the R-appliance (10, 12, 13) (Figures 1 and 2). The patients were instructed to wear the appliances full-time except for eating, contact sports and tooth brushing.

The R-appliance is a tooth and tissue borne appliance. It consists of buccal and lingual shields, which are connected to each other through the occlusal clearance during bite construction. These shields are extended to the distal of the first permanent molars and cover the buccal and lingual regions and the depth of the vestibule. The lingual shield should be fabricated with minimal undercut relieve. The left and right lower lingual shields are connected and reinforced with a heavy archwire (1mm diameter) to withstand the load of muscular activity. A heavy wire (1mm diameter), which acts as a tongue bow, is positioned posterior to connect the right and left acrylic parts on the palatal aspect in order to reinforce the appliance. The labial bow is constructed of 0.7 mm stainless steel wire extended from canine to canine with vertical loops in the canine region. In this group, the construction bites were taken with the upper and lower anterior teeth in an edge to edge occlusion with more than 4 mm of posterior clearance. In other words, the thickness of the connection between buccal and lingual shields would be more than 4 mm. Lateral cephalograms of the patients were taken in centric occlusion at the start (T<sub>1</sub>) and completion (T<sub>2</sub>) of functional treatment. SNA, SNB, ANB, Y-axis (angle between the line connecting Sella to Gnathion and SN), GoGn-SN (angle between SN and mandibular plane), Gonial angle (the angle formed by the junction of the posterior and lower borders of the lower jaw), Inclination

angle (angle between perpendicular line dropped from N-Se at N' and palatal plane),  $\perp$  to SN (angle between long axis upper central incisor and anterior cranial base), IMPA (angle between the long axis of the lower central incisor and mandibular plane), interincisal angle (angle between upper and lower incisors),  $\perp$  to NA (distance between maxillary central incisor to N-A),  $\bar{i}$  to NB (distance between mandibular central incisor to N-B), occlusal to SN (angle between SN and occlusal plane), and Jarabak index (the ratio between posterior and anterior face heights; S-Go/N-Me) were measured on pre and post treatment radiographs.

Two weeks after the first measurements, the tracings and measurements were repeated by one blinded dentist on 10 random cephalograms at the beginning and end of the treatment. To assess the reliability of the measurement, the intraclass correlation coefficients were calculated for each variable in the T<sub>1</sub> and T<sub>2</sub> cephalograms. No significant differences were found between the first and second measurements of those randomly selected cephalograms.

Data were tested for normality and appropriate statistical test were applied. Statistical significance was set at P<0.05. The magnification factor of the cephalograms was standardized at 8 per cent. The Statistical Package for Social Sciences, Version 20 (SPSS Inc. Chicago, Illinois, USA) was used to analyze the data. Paired T-test was used for evaluation of pre and post treatment measurements if the distribution was normal; otherwise, Wilcoxon test was used.

### Results:

After 16 (SD 0.4) months of treatment paired T-tests showed significant ANB decrease of 3.2° (SD 1.6°) (P<0.001) and SNB increase of 3.3° (SD 1.5°) (P<0.001). IMPA significantly decreased from 101° (SD 7.2°) to 98° (SD 9.7°) (P<0.02).  $\perp$  to SN also significantly decreased for 6.1° (SD 5.6°). Jarabak index increased from 59.2% (SD 3.4%) to 61% (SD 3.5%) (P<0.007). Before and after treatment changes can be seen in table 1.

**Table 1: Pre and post treatment cephalometric changes of patients treated by R-appliance**

Landmark	Before Treatment		After Treatment		Difference		P Value
	Mean	SD	Mean	SD	Mean	SD	
SNA °	80	2.6	79.8	2.9	-0.3	1.8	0.5
SNB °	72.8	2.2	76	1.8	3.3	1.5	0.001*
ANB °	7.3	2	4.1	1.8	-3.2	1.6	0.001*
Y-axis °	73.5	3.2	72.7	3	-0.8	1.8	0.07
GoGn-SN °	39.2	4.4	38.6	5	0.6	2.7	0.3
Gonial Angle °	133	5.8	132	5.5	-0.8	2.6	0.2
Inclination Angle °	84.5	2.6	85.7	3.8	1.1	4.9	0.3
U1-SN °	102	7	96	6.5	-6.1	5.6	0.001*
IMPA °	101	7.2	98	9.7	-3	5.4	0.02*
Interincisal Angle °	117.6	9.5	127.8	12	10	8	0.001*
U1-Na (mm)	4	3	2.1	2.6	-1.8	3.4	0.02*
L1-NB (mm)	4.6	1	4.5	1.4	-0.1	0.4	0.6
Occlusal to SN °	23.9	3.5	23.6	3.8	-0.2	3.3	0.7
Jarabak (%)	59.2	3.4	61	3.5	1.7	2.5	0.007*

\* P value was set at 0.05

## Discussion:

Class II division I malocclusion presents either with a prognathic maxilla and a normal mandible, or a normal maxilla and a retrognathic mandible, or even a combination of both. In this study all the cases had mandibular deficiency and were selected solely on the basis of their vertical growth pattern. Use of functional appliances is not recommended for treatment of Class II division I malocclusion cases with high mandibular angle (18, 26). The objective of this study was to verify observations we have made previously in a case study (27) by analyzing a larger number of patients.

In this study, R-appliance improved the skeletal intermaxillary discrepancy in Class II vertical growth pattern patients with mandibular deficiency without proclination of the lower incisors. From a clinical standpoint, the treatment of patients who have high mandibular plane

angle is difficult. During the treatment of a Class II malocclusion patient with a high angle, it is very important to avoid the extrusion of maxillary and mandibular posterior teeth. Equally important, the maxillary and mandibular posterior teeth should be intruded. The connection of lingual and buccal shield of the R-appliance acts as a posterior bite plate and intrudes posterior teeth. The thickness of the connection between lingual and buccal shields can vary at the clinician's discretion depending on the severity of the patient's vertical growth pattern. Normally this thickness is 2 to 3 mm which should be increased as the patient's facial height increases. Nevertheless, there have been reports that bite plate can decrease surface electromyographic activity of masticatory muscles which is probably associated with the smaller number of occlusal contacts (28). Functional appliances are used to correct the Class II

division I malocclusion. An electronic search in literature will reveal copious researches about functional appliances and their effects on mandible (14, 16, 18, 19). During treatment with functional appliances, it has been claimed that forward growth of the maxilla may be inhibited (5, 22, 23). Some studies have reported that the mandibular incisors procline or advance significantly during functional appliance treatment (24, 25, 29, 30, 31). In the R-appliance group the mandible was positioned anteriorly for construction bite. The lingual shield of R-appliance was fabricated with less undercut relief. The undercut relief should be reduced to the extent that it does not irritate the patient (32); however, it should be reduced enough to cause mild trauma. To avoid this trauma all patients were recurrently instructed to posture the mandible forward. This posturing became habitual as patients naturally adopted a comfortable position. In addition, the discomfort caused by reduced relief changed patient's compliance into an unconscious one in the long run. Since the patient moves the mandible forward the protractor muscles are activated and retractor muscles are deactivated. The activation of

protractor muscles would keep mandible forward while the retractor muscles wouldn't have any significant role to pull it back. This active protrusion has a favorable effect on the growth and remodeling of the mandible (33). In addition, this activation prevents headgear effect on maxillary complex and flaring of the lower incisors. Lack of reflex of retractor muscles on the mandible would cause a slight uprighting of the lower incisors.

In this study, the increase of Jarabak index is indicative of the efficacy of R-appliance in treatment of vertical growth pattern patients suffering from Class II malocclusion division 1. This was achieved by increasing the thickness of the connection between lingual and buccal shields which would act as a posterior bit plate.

### Conclusion:

The following conclusions can be drawn on the basis of this study's findings:

- 1- R-appliance resulted in forward positioning of the mandible in Class II division I patients with vertical growth pattern.
- 2- R-appliance did not cause any proclination of lower incisor; moreover, it even reduced their flaring.

## Bibliography

1. Tausche E, Luck O, Harzer W. Prevalence of malocclusions in the early mixed dentition and orthodontic treatment need. *Eur J Orthod.* 2004;26(3):237-244.
2. Perillo L, Masucci C, Ferro F, Apicella D, Baccetti T. Prevalence of orthodontic treatment need in southern Italian schoolchildren. *Eur J Orthod.* 2010;32(1):49-53.
3. McNamara JA, Jr. Components of class II malocclusion in children 8-10 years of age. *Angle Orthod.* 1981;51(3):177-202.
4. Perillo L, Padricelli G, Isola G, Femiano F, Chiodini P, Matarese G. Class II malocclusion division 1: a new classification method by cephalometric analysis. *Eur J Paediatr Dent.* 2012;13(3):192-196.
5. Ghafari J, Shofer FS, Jacobsson-Hunt U, Markowitz DL, Laster LL. Headgear versus function regulator in the early treatment of Class II, division 1 malocclusion: a randomized clinical trial. *Amer J Orthod Dentofacial Orthop.* 1998;113(1):51-61.
6. Tulloch JF, Proffit WR, Phillips C. Influences on the outcome of early treatment for Class II malocclusion. *Am J Orthod Dentofacial Orthop.* 1997;111(5):533-542.
7. Ehmer U, Tulloch CJ, Proffit WR, Phillips C. An international comparison of early treatment of angle Class-II/1 cases. Skeletal effects of the first phase of a prospective clinical trial. *J Orofac Orthop.* 1999;60(6):392-408.
8. Wheeler TT, McGorray SP, Dolce C, Taylor MG, King GJ. Effectiveness of early treatment of Class II malocclusion. *Am J Orthod Dentofacial Orthop.* 2002;121(1):9-17.
9. O'Brien K, Wright J, Conboy F, Sanjie Y, Mandall N, Chadwick S, Connolly I, Cook P, Birnie D, Hammond M, Harradine N, Lewis D, McDade C, Mitchell L, Murray A, O'Neill J, Read M, Robinson S, Roberts-Harry D, Sandler J, Shaw I. Effectiveness of treatment for Class II malocclusion with the Herbst or twin-block appliances: a randomized, controlled trial. *Am J Orthod Dentofacial Orthop.* 2003;124(2):128-137.
10. Jamilian A, Showkatbakhsh R, Kamali Z. R-appliance: a different design in functional therapy in Class II Division I malocclusion. *Int J Orthod Milwaukee.* 2009;20(2):11-14.
11. Maspero C, Galbiati G, Perillo L, Favero L, Giannini L. Orthopaedic treatment efficiency in skeletal Class III malocclusions in young patients: RME-face mask versus TSME. *Eur J Paediatr Dent.* 2012;13(3):225-230.
12. Jamilian A, Showkatbakhsh R, Amiri SS. Treatment effects of the R-appliance and twin block in Class II division 1 malocclusion. *Eur J Orthod.* 2011;33(4):354-358.
13. Showkatbakhsh R, Castaldo MI, Jamilian A, Padricelli G, Fahimi Hanzayi M, Cappabianca S, Perillo L. Treatment effects of R-appliance and Frankel-2 in Class II division 1 malocclusions. *Eur J Paediatr Dent.* 2013;14(1):17-22.

14. Aelbers CM, Dermaut LR. Orthopedics in orthodontics: Part I, Fiction or reality--a review of the literature. *Am J Orthod Dentofacial Orthop.* 1996;110(5):513-519.
15. Perillo L, Castaldo MI, Cannavale R, Longobardi A, Grassia V, Rullo R, Chiodini P. Evaluation of long-term effects in patients treated with Fränkel-2 appliance. *Eur J Paediatr Dent.* 2011;12(4):261-266.
16. Barton S, Cook PA. Predicting functional appliance treatment outcome in Class II malocclusions--a review. *Am J Orthod Dentofacial Orthop.* 1997;112(3):282-286.
17. Morris DO, Illing HM, Lee RT. A prospective evaluation of Bass, Bionator and Twin Block appliances. Part II--The soft tissues. *Eur J Orthod.* 1998;20(6):663-684.
18. McSherry PF, Bradley H. Class II correction-reducing patient compliance: a review of the available techniques. *J Orthod.* 2000;27(3):219-225.
19. Jacobs T, Sawaengkit P. National Institute of Dental and Craniofacial Research efficacy trials of bionator class II treatment: a review. *Angle Orthod.* 2002;72(6):571-575.
20. McNamara JA, Jr., Carlson DS. Quantitative analysis of temporomandibular joint adaptations to protrusive function. *Am J Orthod.* 1979;76(6):593-611.
21. Perillo L, Johnston LE, Jr., Ferro A. Permanence of skeletal changes after function regulator (FR-2) treatment of patients with retrusive Class II malocclusions. *Am J Orthod Dentofacial Orthop.* 1996;109(2):132-139.
22. Voudouris JC, Woodside DG, Altuna G, Angelopoulos G, Bourque PJ, Lacouture CY, Kufnec MM. Condyle-fossa modifications and muscle interactions during Herbst treatment, Part 2. Results and conclusions. *Am J Orthod Dentofacial Orthop.* 2003;124(1):13-29.
23. Toth LR, McNamara JA, Jr. Treatment effects produced by the twin-block appliance and the FR-2 appliance of Frankel compared with an untreated Class II sample. *Am J Orthod Dentofacial Orthop.* 1999;116(6):597-609.
24. Pancherz H. The mechanism of Class II correction in Herbst appliance treatment. A cephalometric investigation. *Am J Orthod.* 1982;82(2):104-113.
25. Vargervik K, Harvold EP. Response to activator treatment in Class II malocclusions. *Am J Orthod.* 1985;88(3):242-251.
26. Ruf S, Pancherz H. The effect of Herbst appliance treatment on the mandibular plane angle: a cephalometric roentgenographic study. *Am J Orthod Dentofacial Orthop.* 1996;110(2):225-229.
27. Jamilian A, Showkatbakhsh R, Rad AT. A novel approach for treatment of mandibular deficiency with vertical growth pattern. *Int J Orthod Milwaukee.* 2012;23(2):23-27.
28. Tecco S, Tete S, D'Attilio M, Perillo L, Festa F. Surface electromyographic patterns of masticatory, neck, and trunk muscles in temporomandibular joint dysfunction patients undergoing anterior repositioning splint therapy. *Eur J Orthod.* 2008;30(6):592-597.
29. Weiland FJ, Ingervall B, Bantleon HP, Droacht H. Initial effects of treatment of Class II malocclusion with the Herren activator, activator-headgear combination, and Jasper Jumper. *Am J Orthod Dentofacial Orthop.* 1997;112(1):19-27.
30. Perillo L, Femiano A, Palumbo S, Contardo L, Perinetti G. Skeletal and dental effects produced by functional regulator-2 in pre-pubertal class II patients: a controlled study. *Prog Orthod.* 2013;26;14:18.
31. Perillo L, Femminella B, Farronato D, Baccetti T, Contardo L, Perinetti G. Do malocclusion and Helkimo Index  $\geq 5$  correlate with body posture? *J Oral Rehabil.* 2011;38(4):242-252.
32. Paolantonio M, D'Ercole S, Pilloni A, D'Archivio D, Lisanti L, Graziani F, Femminella B, Sammartino G, Perillo L, Tetè S, Perfetti G, Spoto G, Piccolomini R, Perinetti G. Clinical, microbiologic, and biochemical effects of subgingival administration of a Xanthan-based chlorhexidine gel in the treatment of periodontitis: a randomized multicenter trial. *J Periodontol.* 2009;80(9):1479-1492.
33. Chavan SJ, Bhad WA, Doshi UH. Comparison of temporomandibular joint changes in Twin Block and Bionator appliance therapy: a magnetic resonance imaging study. *Prog Orthod.* 2014;1;15:57.