

## CLASSIFICATION OF SKELETAL AND DENTAL MALOCCLUSION: REVISITED

Adil Osman Mageet<sup>1a\*</sup>

<sup>1</sup>Department of Orthodontics, MBR University, Hamdan Bin Mohamed College of Dental Medicine, Dubai, UAE

<sup>a</sup>PhD, BDS, CES, MSc (Orthodontics), M.Orth.RCSEd, FDS.RCSEd, Associate Professor

Received: July 02, 2016  
 Revised: July 29, 2016  
 Accepted: August 11, 2016  
 Published: August 12, 2016

### Cite this article:

Mageet AO. Classification of Skeletal and Dental Malocclusion: Revisited. Stoma Edu J. 2016;3(3-4):205-211.

Abstract

DOI: [https://doi.org/10.25241/stomaeduj.2016.3\(3-4\).art.11](https://doi.org/10.25241/stomaeduj.2016.3(3-4).art.11)

**Introduction:** The orthodontic dental classification used dates for more than 100 years. The skeletal and dental classification of malocclusion has an important role in diagnosis and treatment planning. The aim of this study is to facilitate the grouping of skeletal and dental malrelationships and to build an accurate diagnosis and to suggest treatment planning.

**Material and method:** The main orthodontic classification systems for skeletal and dental relationship were reviewed.

**Results:** The proposed skeletal and dental classification proved detailed accuracy and focus on relating the categories with the suggested treatment planning. The new modification of the skeletal and dental classification explained clearly the occlusal relationship and helped in setting treatment strategies.

**Conclusions:** The present skeletal and dental classification is faster, accurate and easily applicable clinically and dealt with the shortcoming of the previous classification systems. It also helped in the suggestion of orthodontic treatment protocols.

**Keywords:** orthodontic malocclusion, skeletal classification, dental classification.

### 1. Introduction

In 1930 Simon was the first to relate the dental arches to the face and cranium in the three planes of space: *Frankfurt horizontal plane* (F-H plane), also called (E-EP). Or-Po plane. Vertical: **Attraction** or **Abstraction**; *Orbital plane* (Perpendicular to F-H plane at the margin of the bony orbit), antero-posterior: **Protraction** or **Retraction**; *Median sagittal plane* (The MSP is determined by points approximate 1.5cm apart on the median raphe of the palate. The raphe median plane passes through these two points at right angles to the F-H plane), transverse: **Contraction** or **Distraction**<sup>1</sup>.

### 2. Material and Method

Salzmann in 1950 was the first to classify the underlying skeletal structure, and he stated that **Skeletal Class I:** Purely dental with the bones of the face and jaws being in harmony with one another and with the rest of the head. The profile is orthognathic (Straight). Then he added divisions to the skeletal I, Division 1: Local mal-relationship of incisors, canines and premolars; Division 2: Maxillary incisor protrusion; Division 3:

Maxillary incisors retrusion; Division 4: Bimaxillary protrusion. **Skeletal Class II:** Distal mandibular development in relation to the maxilla. The profile is prognathic (Convex). He subclassified skeletal II into: Class II/1: Narrow maxillary arch with crowding in the canine region; Class II/2: Lingually Inclined maxillary incisors, the laterals may be normal or proclined. **Skeletal Class III:** Over growth of the mandible with obtuse mandibular angle. The profile is retrognathic profile (Concave)<sup>2</sup>.

Scholar Edward Hingley Angle (1899) classified Orthodontic malocclusion in the mesio-distal relationship of teeth. His classification is based on the maxillary permanent 1<sup>st</sup> molar where he considered it as the key ridge and accordingly he classified the molar relationship into class I, II and III using Roman numbers and subdivided class II into division 1 and 2 using Arabic numbers<sup>3</sup>.

Angle's classification has a number of drawbacks, such as: the Maxillary permanent 1<sup>st</sup> molar is not a fixed anatomic point (key ridge); cannot classify for mesially drifted, impacted, missing or extracted Maxillary permanent 1<sup>st</sup> molars; did not consider single tooth malposition; cannot classify

### \*Corresponding author:

Associate Prof. Dr. Adil Osman Mageet, PhD, BDS, CES (France), MSc (Orthodontic, UK), M.Orth.RCSEd, FDS.RCSEd  
 Department of Orthodontics, Hamdan Bin Mohamed College of Dental Medicine, MBR University, Dubai, UAE , P.O.Box 505097 Dubai UAE  
 Tel: +971 4 424 8631 ; Fax: +971 4 424 8687, e-mail: Adil.mageet@hbmcdm.ac.ae

the primary teeth, in addition did not classify the skeletal relationship and did not predict the etiological factors, so revisiting was always needed. In 1915 Deway's modified Angle's Class I and III malocclusion by segregating malposition of anterior and posterior segments, **CL I**: type 1 (Crowding of Max anterior teeth); type 2 (Proclined Max incisors); type 3 (Max incisors are in cross-bite); type 4 (Posterior cross-bite); type 5 (Mesial drift of molars). **CL II** (no modifications). **CL III**: type 1: (Edge to edge bite), type 2: (Crowded Mandibular incisors and lingual to Max incisors); type 3: (Underdeveloped crowded Maxillary arch and a well developed Mandibular arch)<sup>4</sup>.

Lischer in 1933 further modified Angle's classification by giving substitute names; **CL I** (Neutroclusion); **CL II** (Distocclusion); **CL III** (Mesioclusion). He also proposed terms to designate individual tooth malposition, Mesio-version (Mesial to normal position); Disto-version (Distal to normal position); Linguo-version (Crossbite); Labio-version (Increased OJ); Infra-version (Submerged tooth); Supra-version (Super-erupted); Axio-version (Tipped tooth); Torsi-version (Rotated tooth); Trans-version (Transposed tooth)<sup>5</sup>.

### 3. Results

Ackerman and Proffit (1969) introduced a very comprehensive system of classification using the Venn diagram. The classification considered five characteristics and their inter-relationships were assessed, namely: alignment, profile, transverse, class and overbite<sup>6</sup>.

Angle's classification still seems to be the most popular tool for classification of malocclusion, despite its well-known disadvantages<sup>7</sup>. Hans et al., (1994), noted the inadequacy of Angle's classification when they were unable to classify approximately 7% of a large sample (n=4309) of models in the Broadbent-Bolton study<sup>8</sup>. Another study conducted by Baumrind et al., (1996) on whether to extract in orthodontic treatment, found that 28-33% disagreement among the 5 participating orthodontist<sup>9</sup>.

Katz (1992a) showed an inter-examiner disagreement of 49% among 270 orthodontists using Angle's classification<sup>10</sup>. The percentage agreement of Katz's technique proved superior to that of the classical Angle's classification<sup>11,12</sup>. Rinchuse found Angle's classification to be limited because it is a system of discrete classes as compared to continuous transition of maxillo-mandibular dental arches in the sagittal plane<sup>13</sup>.

The British Standard Institute (BSI) classified dental malocclusion in 1983 according to the maxillary and mandibular incisors relationship.

**Class I**: When the mandibular incisor edges lie or are below the cingulum plateau of the maxillary incisors.

**Class II**: When the mandibular incisor edges lie posterior to the cingulum plateau of the maxillary incisors, the maxillary incisors could be proclined where it is classified as **Class II / 1**, or retroclined

maxillary centrals and proclined laterals, or both central and lateral incisors are retroclined where it is grouped under **Class II / 2**.

**Class III**: where the mandibular incisor edges lie anterior to the cingulum plateau of the maxillary central incisors<sup>14</sup>.

The BSI classification was more accurate in grouping the malocclusion<sup>15</sup>. The British method of overjet and overbite assessment<sup>15</sup> and the quantitative technique proposed by Katz (1992b)<sup>16</sup> developed over the years, proved to be more amenable to reproduction than Angle's classification<sup>11,15</sup>.

In the Du et al. study (1998) in their study where four orthodontic faculty members at one dental school classified 25 dental casts according to the classification systems of Angle, Katz, and the British Incisor Classification<sup>11</sup>. The dental casts were selected from a pool of 350 pretreatment graduate orthodontic cases and were those deemed the most atypical. The results demonstrated that Katz's classification was more reliable than both the Angle and the British one. Angle's classification was the least reliable of the three methods.

## 4. Discussion

### 4.1. Skeletal classification: revisited

In the author's view orthodontic skeletal classification could be grouped into class I (straight), class II (convex) and class III (concave).

Salzmann's classification did not specify that the problem is due to maxillary protrusion, mandibular retrusion or a combination of both.

The same is true for the concave profile, his method did not specify that the problem is due to maxillary retrusion, mandibular protrusion or a combination of both.

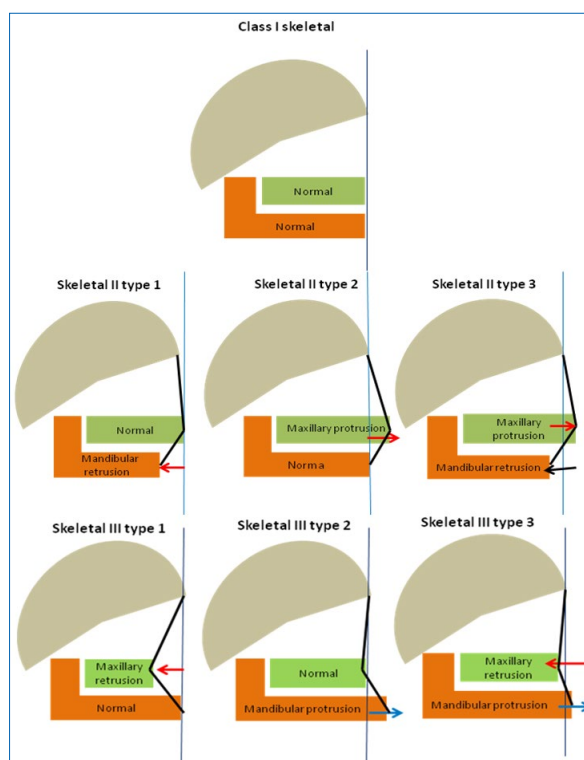
The author agrees with all scholars that skeletal class I has a straight profile (Fig. 1), which explains homogeneous relationship between the maxilla and mandible, or in another terms they grow in unison. In cases of Skeletal I the problem is dental malrelationships. It is present in two planes, the vertical and the transverse planes where the antero-posterior plane is normal or within average.

There is always a question which arises in cases where it is straight to mild convexity or mild concavity.

The author's view is to enlarge the description of skeletal I so as to include the mild convexity and mild concavity as far as it is confirmed by the ANB angle. The range of skeletal I would be straight to mild convexity or mild concavity.

Salzmann's Skeletal II (convex profile) did not indicate either whether it is due to protruded maxilla or retruded mandible or a combination of both. In the present study, Skeletal II could be of three types; type 1 (retruded mandible), type 2 (protruded maxilla) and type 3 (combination of both). (Fig. 1)

The same applies for Class III (concave profile), again Salzmann did not specify either whether it is due to maxillary retrusion or mandibular protrusion. According to my explanation it could be due to maxillary retrusion (Skeletal III type 1), or mandibular protrusion (Skeletal II type 2), or a combination of both



**Figure 1.** Skeletal classification

(skeletal III type 3), which gives detailed explanation aiding in diagnosis and treatment planning. (Fig.1)

#### 4.2. Occlusal Classification: revisited

The BSI and Katz's classification deal with the partial description of the malocclusion.

The British system of classification related to the anterior teeth where it needs further elaboration while Katz's system focuses on the premolar occlusion and ignore the canines and molar classification.

Snyder and Jerrold (2007), have concluded that a modification of Angle's system that is more descriptive is needed, after they have sent an e-mail survey to the department chair or the program director of every orthodontic program in the United States, Canada, and Puerto Rico (n = 80). The survey included photos of models placed into  $\frac{1}{4}$  cusp,  $\frac{1}{2}$  cusp, and  $\frac{3}{4}$  cusp distal occlusions, and the participants were asked to classify them by selecting from a list of terms or writing one of their own.

They were also asked whether they thought that the Angle molar classification was adequate for communication and diagnosis.

Fourty surveys were completed and returned. The results showed a variety of terminology being taught, and most educators do not use Angle's classification as he defined it.

About half of the respondents were dissatisfied with the Angle molar classification system<sup>17</sup>.

In 2002 Siegel conducted 57 surveys which were mailed to department chairs in the United States, asking them to identify the definition to which their orthodontic residency program subscribes; 34 questionnaires were returned.

Twenty-two responses supported the notion that subdivision refers to the Class II side, 8 responses said that it refers to the Class I side, 3 responses supported neither view, and 1 response indicated that in the program not everyone could agree on the meaning of subdivision.

Although the prevailing belief appears to be that subdivision indicates the side with a molar malocclusion, the orthodontic community does not have a consistent standard, and it is time to resolve this controversy<sup>18</sup>.

Due to the low reliability of the Angle method, a reconsideration is needed to develop the older classification.

The reconsideration is done in the antero-posterior and on both sides, where molar classification is more elaborated.

In this revision class IV, V and VI are generated which helped in treatment planning and suggesting treatment protocol.

Skeletal Class III malocclusion was strongly differentiated from the other sagittal classes, specifically in the mandible, as calculated through Björk and Jarabak analysis<sup>19</sup>.

A review article emphasizes the need to identify genetic and environmental factors that cause or contribute risk to skeletal malocclusion and the possible association with other medical conditions to improve assessment, prognosis and therapeutic approaches<sup>20</sup>.

Accurate and detailed classification is always needed to drive an accurate diagnosis and treatment plan.

The author followed the BSI incisor classification with modifications for class II and III, accepts canine classification and modifies molar classification, which are further elaborated for the ease of diagnosis and accuracy of treatment planning in orthodontics.

#### 4.3. Incisor's Classification (Fig. 2)

**Class I:** When the mandibular incisor edges lie or are below the cingulum plateau of the maxillary incisor (BSI, 1983), the overjet is 2-4 mm.

**Class II:** When the mandibular incisors edges lie posterior to the cingulum plateau of the maxillary incisors (BSI, 1983). It could be:

- **Class II/1:** Proclined maxillary incisors with overjet more than 4 mm.

- **Class II/2a:** Retroclined maxillary centrals and proclined laterals, or both central and lateral incisors are retroclined with normal or reduced overjet.

- **Class II/2b:** Retroclined maxillary centrals and proclined laterals, or both central and lateral incisors are retroclined but with increased overjet.

**Class III:** When the mandibular incisors edges lie anterior to the cingulum plateau of the maxillary incisors (BSI, 1983).

- **Class III type 1:** Positive overjet but less than 2 mm.

- **Class III type 2:** Edge to edge incisors relationship.

- **Class III type 3a:** Negative overjet.

• **Class III type 3b:** Negative overjet but patient can make edge to edge (pseudo Class III). The author believes that incisor classification could also be used for esthetic considerations.

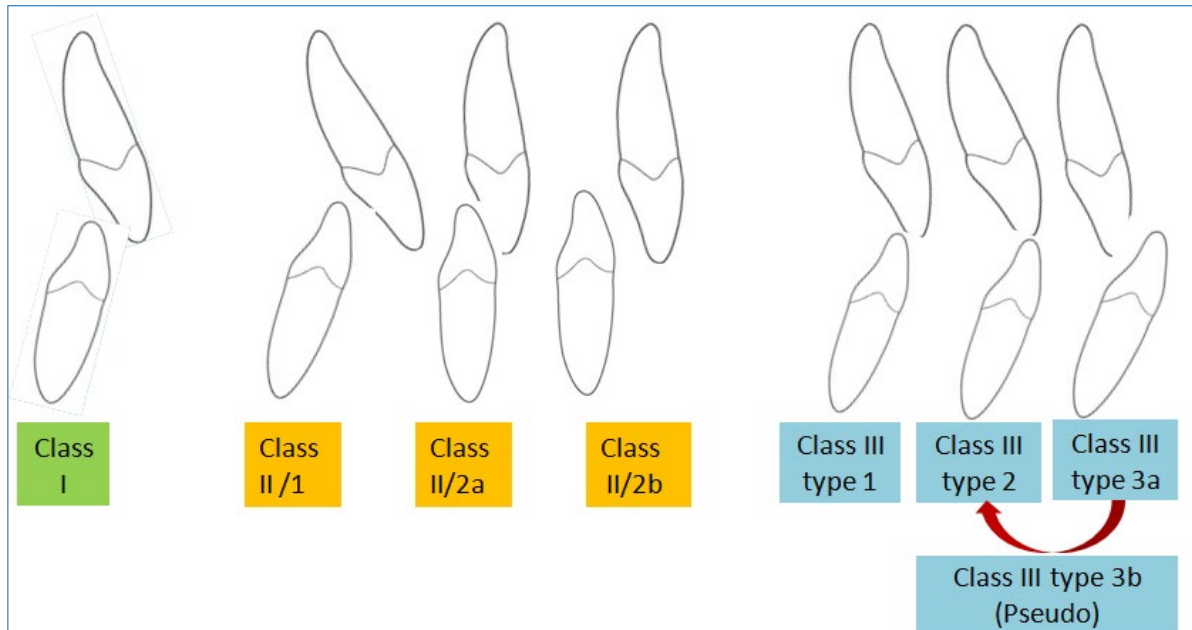
**4.4. Canine's Classification** (Fig. 3)

**Class I:** mesial incline of the upper canine overlaps the distal slope of the lower canine (The maxillary canine occludes between the mandibular canine

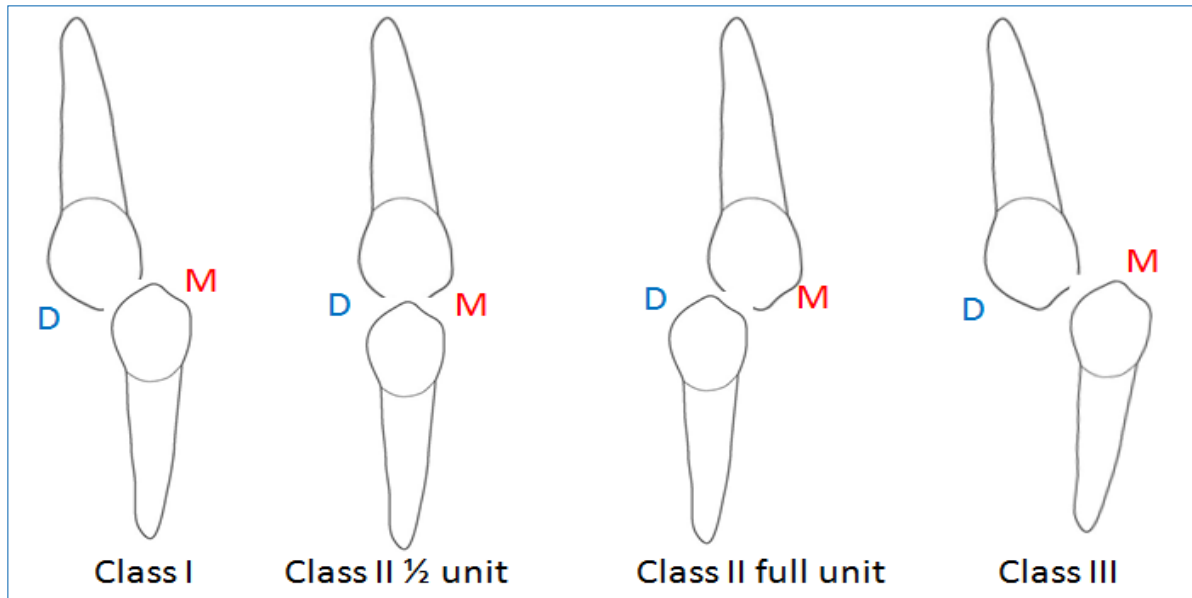
and 1<sup>st</sup> premolar).

**Class II:** Distal slope of the maxillary canine occludes or contacts the mesial slope of the lower canine.

**Class III:** The mandibular canine is displaced anterior to the maxillary canine with no overlapping.



**Figure 2.** Incisor's classification



**Figure 3.** Canine's classification

**4.5. Molar's Classification** (Fig. 4)

The author modified Angle's classification to include different molar relationship on both sides and renamed the subdivision.

**Class I:** The mesio-buccal groove of the mandibular 1<sup>st</sup> permanent molar occludes with the mesio-buccal cusp of the Maxillary 1<sup>st</sup> permanent molar.

**Class II:** The mesio-buccal groove of the mandibular

1<sup>st</sup> permanent molar lie posterior to the mesio-buccal cusp of the Maxillary 1<sup>st</sup> permanent molar.

• **Class II 1/2 unit:** When the maxillary 1<sup>st</sup> permanent molar cusps occlude with the mandibular 1<sup>st</sup> permanent molar cusps in an edge to edge.

• **Class II full unit:** When the maxillary 1<sup>st</sup> permanent molar cusps occlude anterior to the mandibular 1<sup>st</sup> permanent molar.

**Class III.** The mesio-buccal groove of the mandibular 1<sup>st</sup> permanent molar lies anterior to the mesio-buccal cusp of the Maxillary 1<sup>st</sup> permanent molar.

Relationship between right and left buccal occlusion is further grouped to resolve the notion of subdivisions:

**Class IV.** Class I on one side and Class II (either ½ unit or full unit) on the other side.

**Class V:** Class I on one side and Class III on the other side.

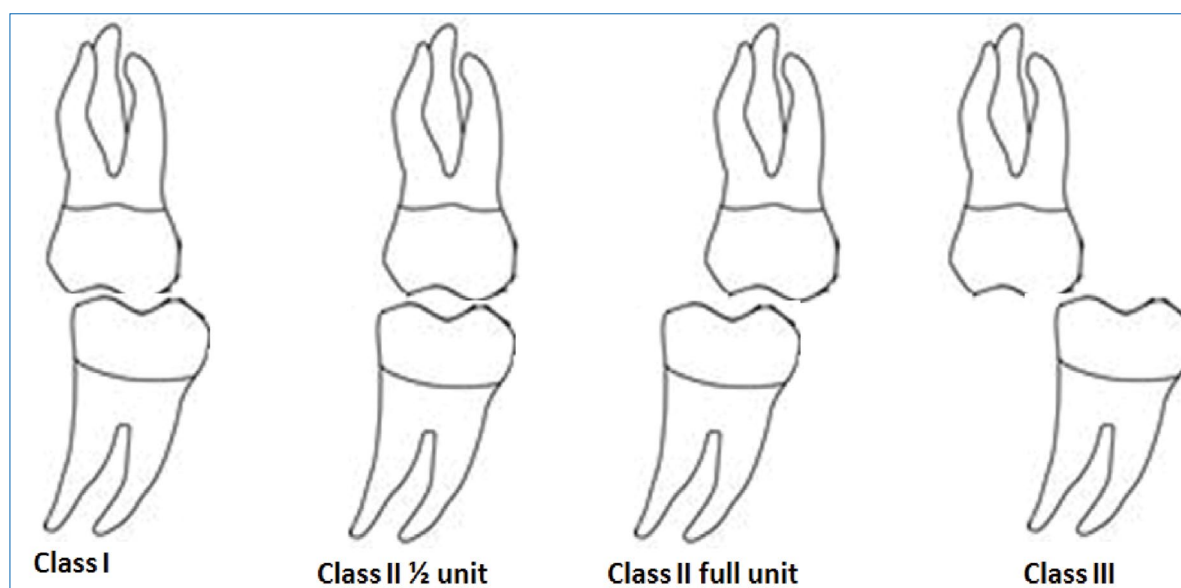
**Class VI:** Class III on one side and Class II (either ½ unit or full unit) on the other side.

Analyzing profile photographs to evaluate sagittal

jaw relationships is a practical tool in determining soft tissue harmony. Soft tissue measurements provide a sagittal differential diagnosis in relation to Angle's classification of malocclusion<sup>21</sup>.

A suggested treatment protocol is easily derived from the present classification skeletal (Table 1) and dental (Table 2).

This varies from mechanics to mechanics, but the idea is to help the undergraduate to understand orthodontic diagnosis and treatment planning and for postgraduate residents and orthodontists to formulate accurate stable orthodontic treatment results.



**Figure 4.** Molar's classification

**Table 1.** Suggested treatment protocol for skeletal bases

Skeletal I		There is a harmonious relationship antero-posteriorly; the problem is either in the vertical or transverse plane. Advice surgical correction if needed.
Skeletal II	Type 1	Functional appliance (growing children) or mandibular surgery (adult or syndromic patients e.g. Pierre Robin).
	Type 2	Headgear (children and adolescents) or maxillary surgery for adults.
	Type 3	Here the treatment could of combination, functional [removable e.g. twin block or fixed e.g. Forsus], Headgear, camouflage with the extraction of upper 1 <sup>st</sup> premolars alone or in combination with lower 2 <sup>nd</sup> premolars or Bi-maxillary orthognathic surgery.
Skeletal III	Type 1	Functional appliances e.g. Yanagisawa Class III shield (YC3) <sup>19</sup> . Palatal expansion ± facemask (Delaire, reverse pull headgear by Nakamura) advised before the age of 10 years. <sup>20</sup>
	Type 2	Mandibular excess is treated with surgery e.g. Bilateral sagittal split osteotomy (BSSO).
	Type 3	Here the treatment could of combination: functional (Yanagisawa, YC3), palatal expansion ± facemask, camouflage with the extraction of lower 1 <sup>st</sup> premolar and upper 2 <sup>nd</sup> premolars, or extraction of a single lower central incisor, Bi-maxillary orthognathic surgery (Le Fort I ± BSSO) or genioplasty in some cases.

**Table 2.** Suggested treatment protocol for dental malocclusion

Class I malocclusion		<p><b>Non extraction:</b> stripping, expansion, derotation, uprighting or distalisation</p> <p>Extraction: U/L 4s, U/L 5s, U/L 6s, U/L 7s or a symmetric extraction e.g. right U/L 4s + left U/L 5s, U/L 6s + U/L 4s or 5s, single tooth extraction.</p>
Class II malocclusion	Type 1	<p><b>Non extraction:</b> Distalisation with headgear</p> <p>Extraction: 4s, (U 4s + L 5s), (U/L 6s), (U/L 7s) or a symmetric extraction e.g. (right U/L 4s + left U/L 5s), (U/L 6s + U/L 4s or 5s), or a single U4.</p>
	Type 2a	<p>Always advise non extraction treatment using a headgear + Nudger or an intra-oral distalizer.</p> <p>If crowding is to be relieved by extraction, then it is advisable to extract the 2<sup>nd</sup> premolar than the 1<sup>st</sup> premolar because of difficulty of space closure.</p> <p>Transfer the case to CL II/1 and treat accordingly.</p>
	Type 2b	<p>Headgear + Nudger</p> <p>Orthognathic surgery treatment (proclined upper anteriors and retroclined lower anteriors-decompensation: plan for surgery)</p>
Class III malocclusion	Type 1	<p>Camouflage with stripping lower arch and proclining upper teeth.</p> <p>Expansion of upper arch ± fixed appliance therapy.</p>
	Type 2	<p>Expansion of upper arch ± fixed appliance therapy with CL III elastics.</p> <p>Extraction of lower 1<sup>st</sup> premolars and upper 2<sup>nd</sup> premolars + U/L fixed orthodontic therapy with CL III elastics.</p> <p>Expansion of upper arch + extraction of a single lower central incisor + U/L fixed orthodontic therapy with CL III elastics.</p>
	Type 3a	<p>Expansion of upper arch ± fixed appliance therapy with CL III elastics.</p> <p>Extraction of lower 1<sup>st</sup> premolars and upper 2<sup>nd</sup> premolars + U/L fixed Orthodontic therapy with CL III elastics.</p> <p>Expansion of upper arch + extraction of a single lower central incisor + U/L fixed orthodontic therapy with CL III elastics.</p>
	Type 3b	<p>Expansion of upper arch ± fixed Orthodontic therapy.</p> <p>Extraction of lower 1<sup>st</sup> premolars and upper 2<sup>nd</sup> premolars + U/L fixed Orthodontic therapy.</p> <p>Expansion of upper arch + extraction of a single lower central incisor + U/L fixed Orthodontic therapy with CL III elastics.</p>

**5. Conclusion**

Incisor, canine and molar classification should always be used accurately to diagnose and to plan the final occlusion.

A final class I incisor and canine relationship at the end of treatment is always the aim **so to provide** long term stability while molar relationship could be class I, II (full unit) or III relationship.

The author recommends further study on methods of classification and establishing orthodontic treatments' protocols.

**Acknowledgments**

The author declares no conflict of interest related to this study. There are no conflicts of interest and no financial interests to be disclosed.

REFERENCES

- Simon PW. Grundzüge einer systematischen Diagnostik der Gebiss-Anomalien. Berlin: Hermann Meusser; 1922.
- Salzmann JA. Practice of orthodontics. Philadelphia: J. B. Lippincott Company; 1966.
- Angle EH. Classification of malocclusion. Dental Cosmos. 1899;41(3):248-264.
- Dewey M. Classification of malocclusion. Int J Orthod. 1915; 1(3): 133-147.
- Lischer BE. Principles and Methods of Orthodontics. Philadelphia: Lea and Febiger; 1912.
- Ackerman JL, Proffit WR. The characteristics of malocclusion: a modern approach to classification and diagnosis. Am J Orthod. 1969; 56(5): 443-454.
- Katz MI, Sinkford JC, Sanders CF Jr. The 100-year dilemma: what is a normal occlusion, and how is malocclusion classified? Quintessence Int. 1990; 21(5): 407-414.
- Hans MG, Broadbent BH Jr, Nelson SS. The Broadbent-Bolton Study—past, present and future. Am J Orthod Dentofacial Orthop. 1994; 105(6): 598-603.
- Baumrind S, Korn EL, Boyd RL, Maxwell R. The decision to extract: Part 1—Interclinician agreement. Am J Orthod Dentofacial Orthop. 1996;109(3):297-309.
- Katz MI. Angle classification revisited 1: Is current use reliable? Am J Orthod Dentofacial Orthop. 1992; 102(2): 173-179.
- Du SQ, Rinchuse DJ, Zullo TG, Rinchuse DJ. Reliability of three methods of occlusion classification. Am J Orthod Dentofacial Orthop. 1998; 113(4): 463-470.
- Brin I, Weinberger T, Ben-Chorin E. Classification of occlusion reconsidered. Eur J Orthod. 2000; 22(2): 169-174.
- Rinchuse DJ, Rinchuse DJ. Ambiguities of Angle's classification. Angle Orthod. 1989; 59(4): 295-298.
- British Standards Institute. Glossary of Dental Terms (BS 4492). London: BSI; 1983.
- Williams AC, Stephens CD. A modification to the incisor classification of malocclusion. Br J Orthod. 1992; 19(2): 127-130.
- Katz MI. Angle classification revisited 2: a modified Angle classification. Am J Orthod Dentofacial Orthop. 1992; 102(3): 277-284.
- Snyder R, Jerrold L. Black, white, or gray: finding commonality on how orthodontists describe the areas between Angle's molar classifications. Am J Orthod Dentofacial Orthop. 2007; 132(3): 302-306.
- Siegel MA. A matter of Class: interpreting subdivision in a malocclusion. Am J Orthod Dentofacial Orthop. 2002; 122(6): 582-586.

19. Rodriguez-Cardenas YA, Arriola-Guillen LE, Flores-Mir C. Björk-Jarabak cephalometric analysis on CBCT synthesized cephalograms with different dentofacial sagittal skeletal patterns. *Dental Press J Orthod.* 2014; 19(6): 46-53.
20. Joshi N, Hamdan AM, Fakhouri WD. Skeletal malocclusion: a developmental disorder with a life-long morbidity. *J Clin Med Res.* 2014 Dec; 6(6): 399-408.
21. Wasserstein A, Shpack N, Ben Yoseph Y, Geron S, Davidovitch M, Vardimon A. Comparison of lateral photographic and radiographic sagittal analysis in relation to Angle's classification. *J Orofac Orthop.* 2015; 76(4): 294-304.
22. Onodera K, Niikuni N, Yanagisawa M, Nakajima I. Effects of functional orthodontic appliances in the correction of a primary anterior crossbite—changes in craniofacial morphology and tongue position. *Eur J Orthod.* 2006; 28(4): 373-377.
23. Mandall N, DiBiase A, Littlewood S, Nute S, Stivaros N, McDowall R, Shargill I, Worthington H, Cousley R, Dyer F, Mattick R, Doherty B. Is early Class III protraction facemask treatment effective? A multicentre, randomized, controlled trial: 15-month follow-up. *J Orthod.* 2010; 37(3): 149-161.

### Adil Osman MAGEET

PhD, BDS, CES (France), MSc (Orthodontic, UK), M.Orth.RCSEd, FDS, RCSEd, Associate Professor, Consultant Orthodontist  
Department of Orthodontics  
Hamdan Bin Mohamed College of Dental Medicine  
MBR University, Dubai, UAE , P.O.Box 505097 Dubai, UAE



## CV

Licensed by CPQ (UAE), the Saudi Commission for Higher Specialties and the Sudanese Medical Council as a consultant orthodontist. I treat orthodontic problems from mild to complex cases with a variety of treatment options, removable, functional, fixed, clear orthodontics, orthodontic part of orthognathic surgery and cleft lip / palate cases. I also manage snorers and mild to moderate obstructive sleep apnoea hypopnoea patients using intra-oral appliances. I have been working as an orthodontist for the past 20 years. Examiner of the RCSEd for the 2<sup>nd</sup> part MFDS and the M. Orth. Reviewer of the Oral Hygiene and Dental Management Journal. Published many articles in reputable journals.

## Questions

**An 11 year-old female patient with a chief complaint “my upper teeth are crowded”. She presented a Class II/2 incisor relation, class II ½ unit canines and molars, on Skeletal II base deep bite and centre line shift. Lateral cephalometry shows SNA of 84°, SNB 78° ANB of 6° and decreased maxillary mandibular plane angle. The treatment would be:**

- a. Extraction of 14 and 24 with upper and lower fixed Orthodontics treatment;
- b. Distalisation of upper 16 and 26 by HG and a Nudger appliance with upper and lower fixed
- c. Extraction of 14, 24, 35 and 45 with upper and lower fixed Orthodontics;
- d. Transfer the case to CL II/1 and treat with functional appliance and treat accordingly.

**What is the treatment of choice in case of skeletal Class III cases is with reduced anterior cranial base and retruded maxilla in a 9 year-old boy.**

- a. Rapid palatal expansion alone;
- b. Functional appliance and fixed Orthodontics;
- c. Rapid palatal expansion and Face mask;
- d. Orthognathic surgery by Le Fort I osteotomy.

**How do you define Class II/2b incisor relation from the article:**

- a. Upper incisors retroclined laterals are procline;
- b. All upper anteriors are retroclined with increased overjet;
- c. All upper anteriors are retroclined with a deep bite;
- d. Upper incisors retroclined laterals are procline.

**Define skeletal Class III type 3 from the paper:**

- a. Retruded maxilla;
- b. Retruded maxilla with protruded mandible;
- c. Straight profile;
- d. Protruded maxilla.