

MODIFIED CLINICAL APPROACH FOR IMPROVED AESTHETICS IN FULL-ARCH RESTORATION

Henriette Lerner^{1*}, Zhimon Jacobson^{2b}

¹HL-Dentclinic, Baden-Baden, Germany

²Department of Restorative Sciences & Biomaterials, Henry M. Goldman School of Dental Medicine (GSDM), University of Boston, USA

^aDMD, Associate Professor, Director HL-DENTCLINIC

^bDMD, MSD, Clinical Professor

Received: 10 August 2015
Received in revised form: February 28, 2016
Accepted: 27 April 2016
Published online: January 19, 2016

Cite this article:

Lerner H, Jacobson Z. Modified clinical approach for improved aesthetics in full-arch restoration. *Stoma Edu J*. 2016; 3(1-2):68-74.

ABSTRACT

[https://doi.org/10.25241/stomaeduj.2016.3\(1-2\).art.10](https://doi.org/10.25241/stomaeduj.2016.3(1-2).art.10)

Aim: to achieve a natural aesthetic outcome, function and stability using a minimally invasive, maximally effective technique in a reasonable time period.

Summary: A 50-year-old female patient presented a tooth mobility of Grade II to III. She wished to have a full arch fixed aesthetic restoration. After evaluation of the hard and soft tissue and minimally invasive planning, the decision was made to modify the clinical approach and create a special protocol for best aesthetic results. The treatment includes chairside and laboratory steps, such as aesthetic analysis, impressions, a functional analysis, X-rays, CT, and evaluation of the hard and soft tissue, a mock-up of the intended result and minimally invasive planning. The patient was happy with the desired outcome.

Key learning points:

1. Improved aesthetic results for full arch restorations are achieved by immediate implant placement, immediate loading and platform switching.
2. Platform switching implant design, provisional and final abutment design, and paradigm shifts in treatment approaches lead to superior aesthetic results.
3. Thorough evaluation and manipulation of the hard and soft tissue provide the desired aesthetic outcome.

Keywords: aesthetic implantology, pink and white aesthetics, full arch restoration, inter-implant papilla length, platform-switching.

1. Introduction

This case study demonstrates that new philosophies concerning implant design, provisional and final abutment design, as well as paradigm shifts in treatment approaches, can lead to superior aesthetic results. In full-arch implant-supported restoration, immediate placement with immediate loading has been well documented. The literature shows a high success rate of 97% with this kind of treatment in the mandible¹¹⁻¹⁷ and of 96% in the maxilla.¹⁸⁻²⁰ Osseointegration of implants has been achieved routinely and with a high degree of success. Contemporary implant dentistry focuses on aesthetic success aside from functional results. One of the compromises in aesthetics in a situation of adjacent implants is the short papilla between two implants, where a maximum length of 3.5 mm can be achieved.¹ This can be explained by loss of the inter-implant bone. The advantages of a platform-switched implant design regarding

bone and tissue stability are well documented in literature.²⁻⁶ The resulting stability of the bone is explained through the increased distance of the micro-gap from the bone (a minimum of 0.45 mm is adequate). Another way to preserve bone in the long term is by selecting an implant design with a micro-thread design at the collar. The positive influence of the micro-thread design at the collar of the implant has been biomechanically explained by Steigenga et al.⁷ Bone is stronger when loaded in compression, and 30% weaker when subjected to tensile forces. During function, the shear forces are transformed into small compression and traction forces.

2. Papillary area

Another observed benefit of platform-switching is the non-surgical increase in tissue volume in the healing phase.

Additionally, Gargiulo⁸ has demonstrated that the

*Corresponding author:

Associate Professor Henriette Lerner, DMD, Director HL-Dentclinic
Ludwig-Wilhelm-Straße 17, D-76530 Baden-Baden, Germany
Phone: +49 (0) 7221.398730, Fax: +49 (0) 7221.3987310, e-mail: info@hl-dentclinic.de

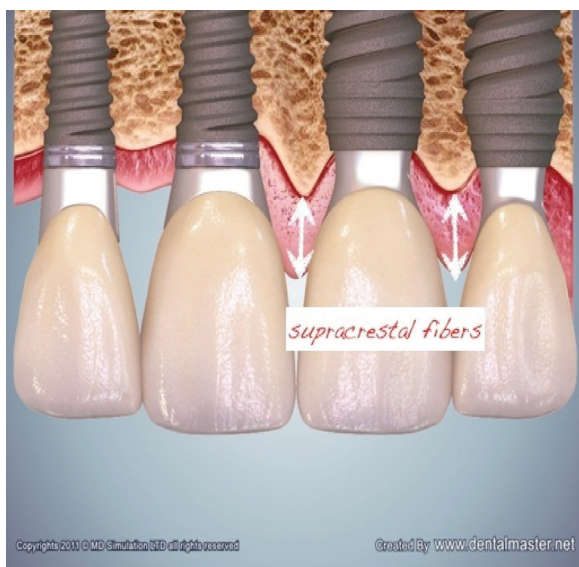

Figure 1. The platform-switching design of the implants facilitated preservation of bone at the collar and the gaining of supra-crestal fibres

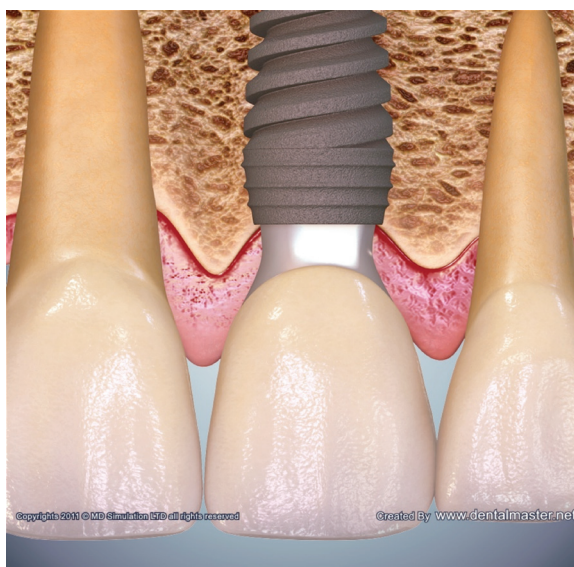

Figure 2. Concave profile of the provisional abutment.

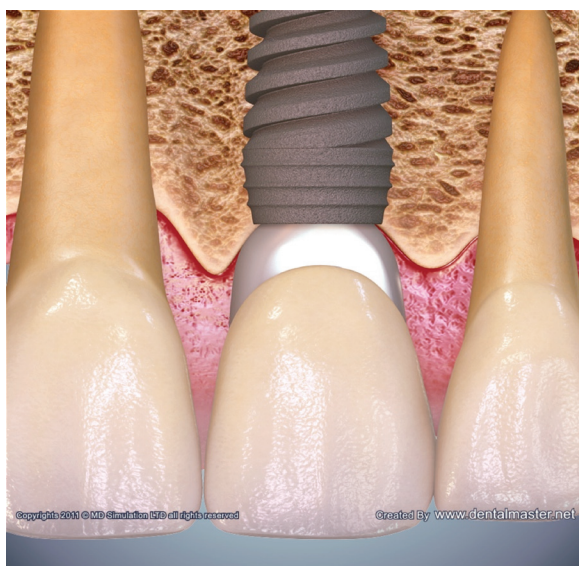

Figure 3. Convex profile of the final individual abutment

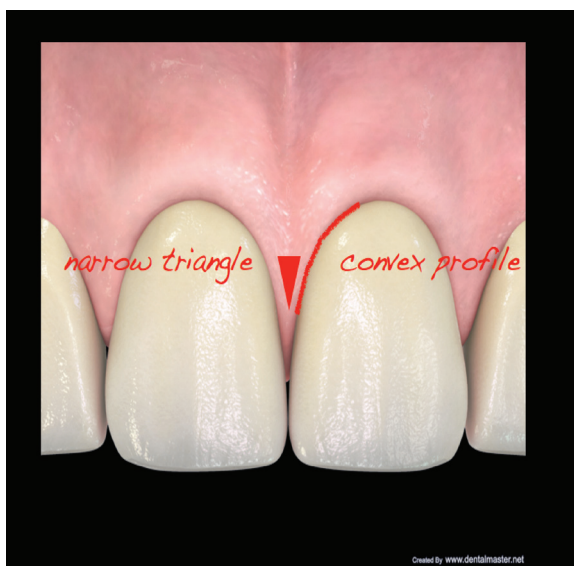

Figure 4. Narrow triangles between the final crowns, restoring the physiological and aesthetic contact points

higher the peri-implant soft tissue, the lower the risk of bone loss in the process of increasing the biological width.⁸

Through decreased bone loss and a resulting reduction in bone instability, as well as increased thickness of the tissue, more supra-crestal fibres can be gained (Fig. 1).

Owing to this concept in designing the provisional abutment, the final abutment and the crown, we were able to manipulate the soft tissue and gain an inter-implant papilla length comparable to the length of the papilla between two natural teeth (5 mm).

3. Abutment

The running room for the provisional abutment

was concave (Fig. 2).⁹ After osseointegration, we modified the running room to a straight or slightly convex profile, especially approximately. The tissue extended from 0.5 to 1 mm in the direction of the contact point (Fig. 3). The final construction followed the natural parameters of the interdental contact points in the natural dentition, as defined by Chu et al.¹⁰ Designing the interdental spaces as narrow triangles with slight convexities, we managed to guide this tissue by another 0.5 to 1 mm to the ideal contact point, and give the entire construction a natural appearance (Fig. 4).

4. Clinical case

A 50-year-old patient presented a tooth mobility of Grade II to III (Fig. 5). He wished to have his

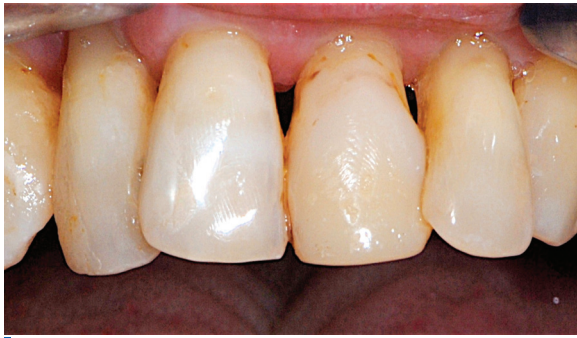

Figure 5. Periodontally damaged teeth, mobility Grade II

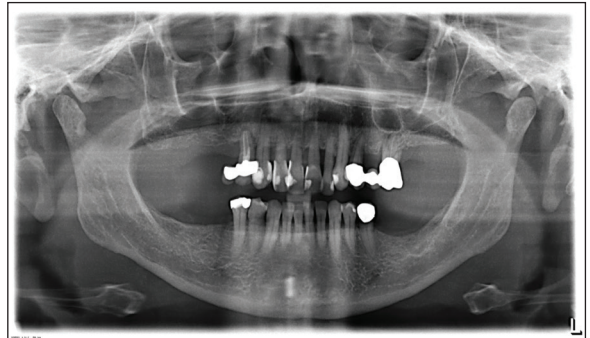


Figure 6. Horizontal bone loss

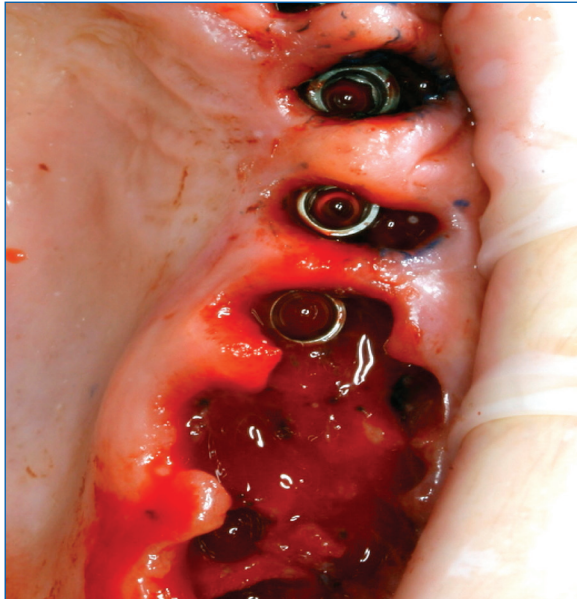


Figure 7. Immediate implant placement with immediate loading

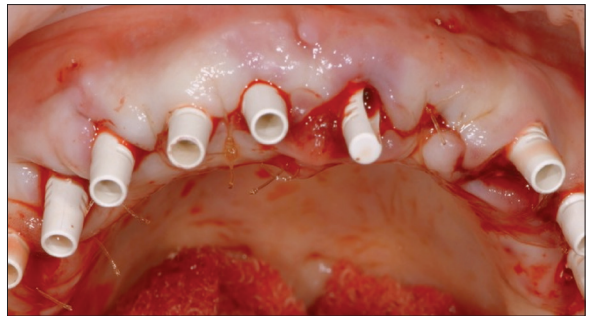

Figure 8. PEEK abutments

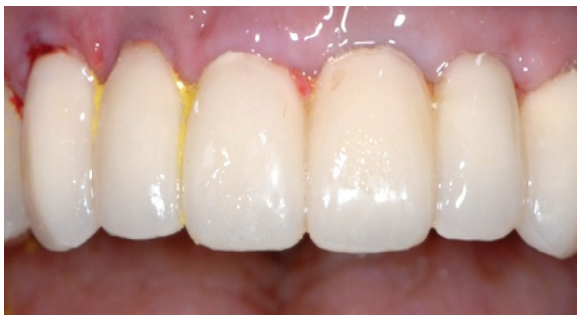

Figure 10. Periodontally damaged teeth, mobility Grade II



Figure 9. Provisional PEEK abutment with concave running room

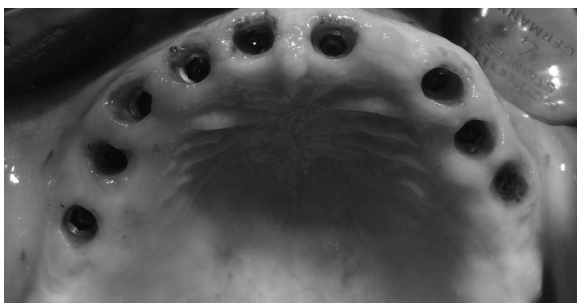

Figure 11. Situation after healing/osseointegration

aesthetic restoration fixed. In cases such as this, an alternative chairside and laboratory workflow can guide our treatment.

The chairside workflow included an aesthetic analysis, impressions, a functional analysis, X-rays, CT, and evaluation of the hard and soft tissue (Fig. 6). The treatment plan should be minimally invasive, of maximum effectiveness and aim for the best aesthetic results. This means immediate implant placement and immediate loading (Fig. 7).

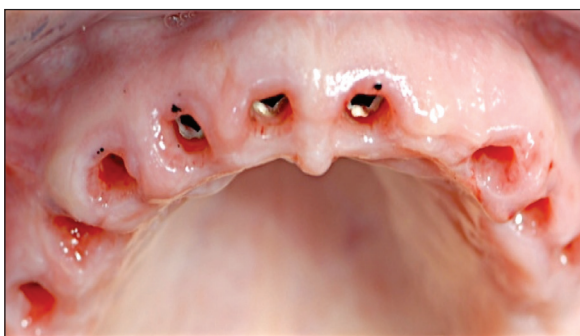


Figure 12. After healing



Figure 13. Modification of the soft-tissue biotype to a straight or slightly convex profile

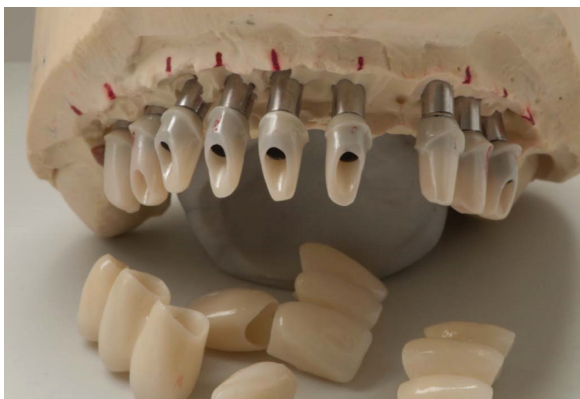

Figure 14. Individually fabricated zirconia abutments (LAVA) on a titanium base, with a preparation limit of 0.5 mm below the gingival margin

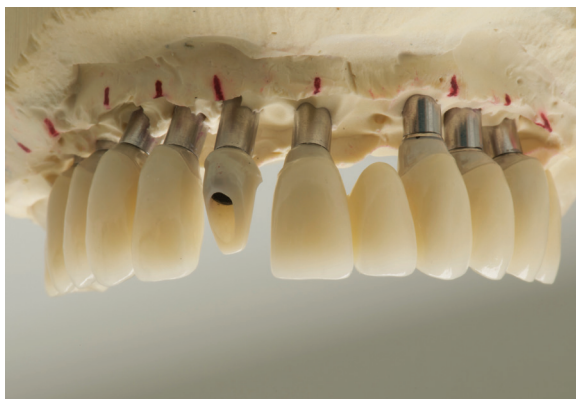

Figure 15. Individually fabricated zirconia CAD/CAM abutments and IPS e-max lithium disilicate (Ivoclar Vivadent) ceramic crowns

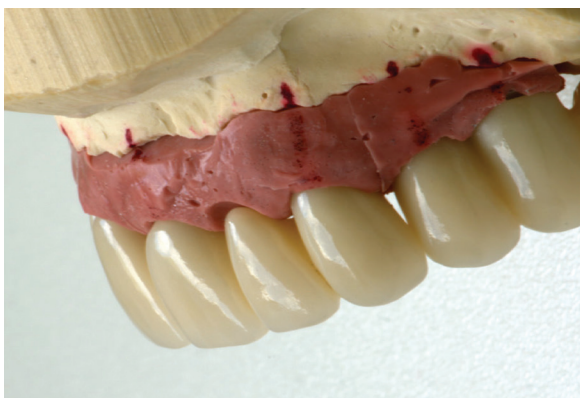

Figure 16. Manipulation of the soft tissue to achieve the desired aesthetic outcome

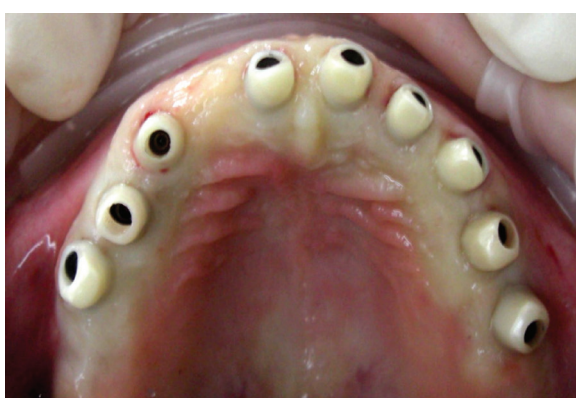


Figure 18. Insertion of the abutments, allowing one minute of compression

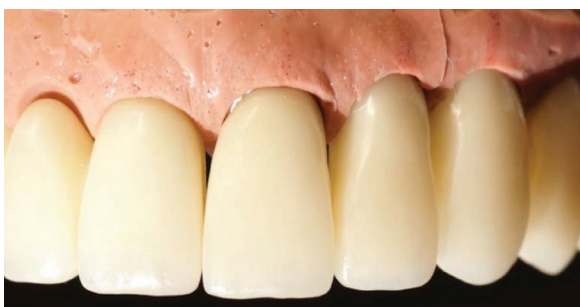

Figure 17. Aesthetic gingival outcome shown on the model

At the laboratory, a mock-up of the intended result was created. Afterwards, the mock-up was

discussed with the patient and tried in chairside. At the next appointment, implant placement using a provisional and surgical, aesthetic-driven guide, fabricated by the laboratory in advance, and immediate restoration followed the chairside stage.

The implants were selected in order to allow immediate loading. For immediate loading, an implant's features and insertion protocol have to provide for high primary stability. Therefore, self-cutting threads and a drilling protocol

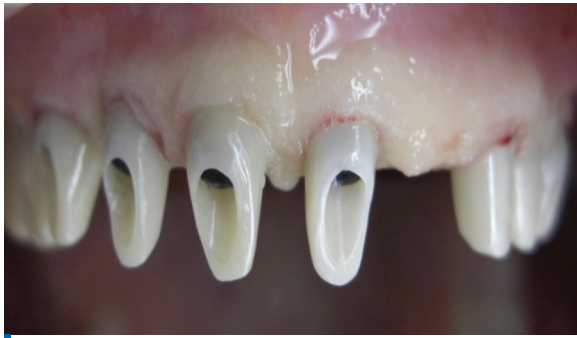

Figure 19. Positive effect on the length of the papilla

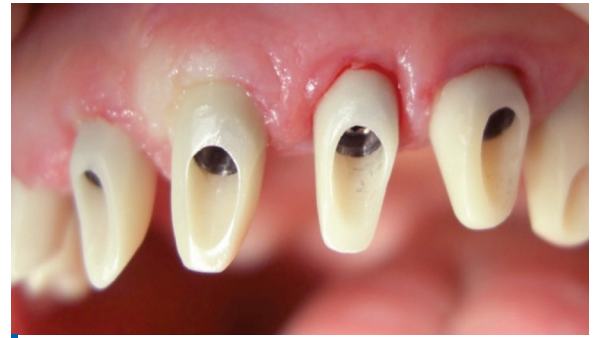

Figure 20. Revascularisation after one minute

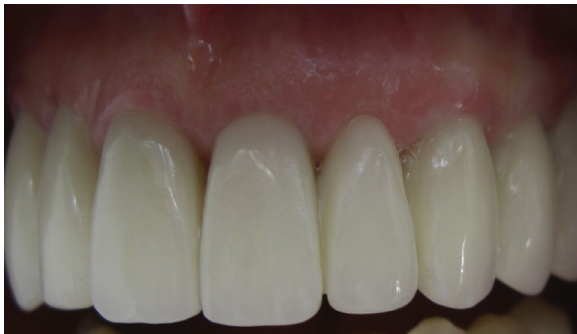

Figure 21. Crowns inserted

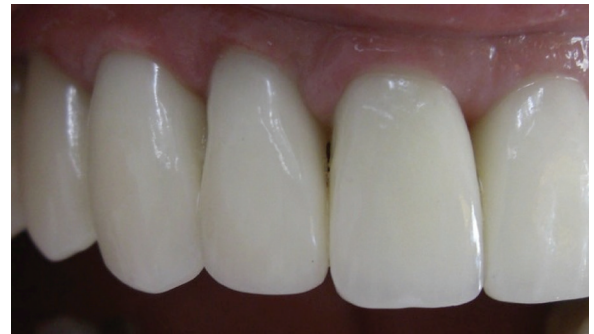

Figure 22. Situation after inserting the crowns

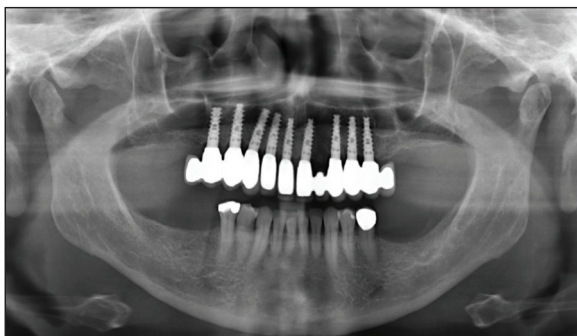


Figure 23. Restoration

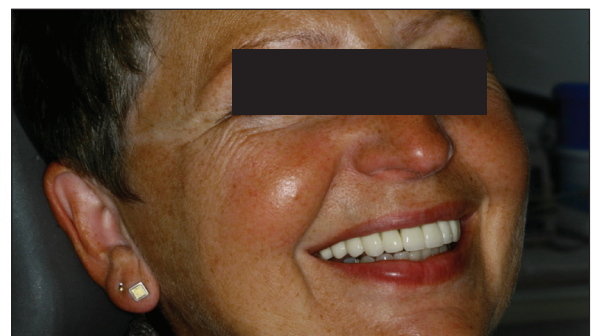

Figure 25. Pleasing aesthetic outcome

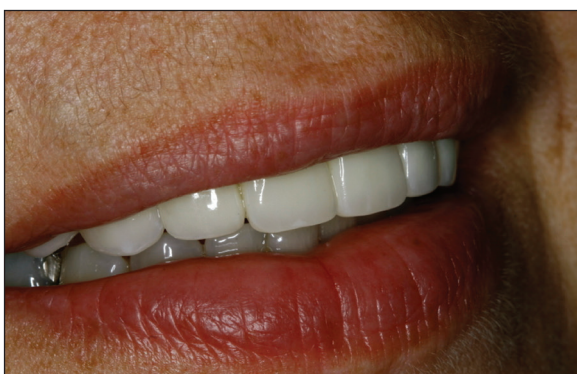

Figure 24. Natural-looking outcome

for undersized implant site preparation were necessary. Furthermore, the rough surface of the implant shoulder and the micro-thread design at the collar were important for long-term bone and soft-tissue stability. Platform-switched provisional abutments with concave running room and made of PEEK (polyether ether ketone) were additional

features that qualified the implant selected for immediate loading (Figs 8, 9).

Another important aspect covered the parameters applied in the immediate loading of the implants inserted in extraction sockets. Primary stability was achieved with an insertion torque of 35 N cm. About three quarters of the implant surface should be covered by the host bone. The gap between the implant and the buccal bone was augmented to a maximum of 1.5 mm (Tarnow, 1997). Owing to these conditions, we were able to insert immediate implants and to perform immediate loading with a rigid fixed bridge (Figs 10-12). Individual abutments were CAD/CAM fabricated from zirconia (LAVA, 3M ESPE) (Fig. 13). Tooth reconstruction was employed to produce the bridge (Figs 14-17).

Individually, the running room was modified to a slightly convex or straight profile, so that the tissue was shifted interdental and another 0.5 to 1 mm

was gained in papilla length. The convexities of the crown contour at the gingival margin were produced with respect to the harmony of the pink and white aesthetics (Figs 18-22).

Symmetry, the golden proportion and the individual demands of the patient were given particular consideration (Figs 23-25).

5. Conclusion

The target of modern dentistry is the achievement of a natural aesthetic outcome, function and stability using a minimally invasive, maximally effective technique and in a reasonable period. The treatment method presented herein, with the main aim of imitating or even improving the natural dentition, has been used for 12 full-arch cases over the last two years. In order to obtain the natural gingival architecture between implants, we adhere to the following:

1. immediate implant placement in perfect implant position;
2. immediate loading of the implant under initial stable conditions;

3. use of implant systems with a platform-switching design;
4. use of provisional abutments with a convex profile;
5. use of provisional crowns with a flat profile;
6. use of final abutments with a slightly convex profile to move the tissue gained into the interdental space;
7. restoration of the natural proportion of the interdental spaces and contact points; and
8. creation of narrow triangles, forming space for the papillae.

The authors wish to acknowledge Roland Danneberg, master technician, for the prosthetic work.

All images were created in Dental Master. Material copyright by MD Simulation Ltd (www.dentalmaster.net).

Acknowledgments

The authors declare no conflict of interest related to this study. There are no conflicts of interest and no financial interests to be disclosed.

REFERENCES

1. Salama H, Salama MA, Garber D, Adar P. The interproximal height of bone: a guidepost to predictable aesthetic strategies and soft tissue contours in anterior tooth replacement. *Pract Periodontics Aesthet Dent.* 1998;10(9):1131-1141.
2. Hürzeler M, Fickl S, Zuhr O, Wachtel HC. Peri-implant bone level around implants with platform-switched abutments: preliminary data from a prospective study. *J Oral Maxillofac Surg.* 2007;65(7 Suppl 1):33-39.
3. Vigolo P, Givani A. Platform-switched restorations on wide-diameter implants: a 5-year clinical prospective study. *Int J Oral Maxillofac Implants.* 2009;24(1):103-109.
4. Lazzara RJ, Porter SS. Platform switching: a new concept in implant dentistry for controlling postrestorative crestal bone levels. *Int J Periodontics Restorative Dent.* 2006;26(1):9-17.
5. Cappiello M, Luongo R, Di Iorio D, Bugea C, Cocchetto R, Celletti R. Evaluation of peri-implant bone loss around platform-switched implants. *Int J Periodontics Restorative Dent.* 2008;28(4):347-355.
6. Schrotenboer J, Tsao YP, Kinariwala V, Wang HL. Effect of microthreads and platform switching on crestal bone stress levels: a finite element analysis. *J Periodontol.* 2008;79(11):2166-2172.
7. Steigenga JT, al-Shammari KF, Nociti FH, Misch CE, Wang HL. Dental implant design and its relationship to long-term implant success. *Implant Dent.* 2003;12(4):306-317.
8. Gargiulo AW, Wentz FM, Orban B. Dimensions and relations of the dentogingival junction in humans. *J Periodontol.* 1961;32(3):261-267.
9. Su H, Gonzalez-Martin O, Weisgold A, Lee E. Considerations of implant abutment and crown contour: critical contour and subcritical contour. *Int J Periodontics Restorative Dent.* 2010;30(4):335-343.
10. Chu SJ, Tarnow DP, Tan JH, Stappert CF. Papilla proportions in the maxillary anterior dentition. *Int J Periodontics Restorative Dent.* 2009;29(4):385-393.
11. Misch CE, Wang HL, Misch CM, Sharawy M, Lemons J, Judy KW. Rationale for the application of immediate load in implant dentistry: part II. *Implant Dent.* 2004;13(4):310-321.

Henriette LERNER

DMD, Associate Professor
Director HL-Dentclinic
Baden-Baden, Germany

**CV**

Henriette Lerner is associate professor at the “Grigore T. Popa” University of Medicine and Pharmacy Jassy, Romania, and Director of HL Dentclinic as well as HL Academy (Affiliate to Seattle Study Club) in Baden-Baden, Germany.

Since 1990 she was granted the DMD degree from the Faculty of Dental Medicine, “Victor Babeş” University of Medicine and Pharmacy, Temeschburg, Romania. Her domain expertise is in the fields of advanced techniques of augmentation, soft tissue management, aesthetics and function in complex implant cases, minimally invasive implantology and digital virtual planning. Amongst other certifications, she is an ICOI Diplomate (International Congress of Oral Implantologists).

She is Director of DGOI Implantology Expert (German Society of Oral Implantology) and author of various research papers mainly covering the area of implantology and dental surgery.

Questions**Which was not included in the treatment presented in this article?**

- a. MRI;
- b. CT;
- c. X-ray;
- d. Functional analysis.

What tooth mobility did the patient have?

- a. Grade I;
- b. Grade II to III;
- c. Grade 0;
- d. None of the above.

What do the implant's features and insertion need to provide for high primary stability?

- a. Low primary stability;
- b. Medium primary stability;
- c. High primary stability;
- d. None of the above.

How much of the implant surface should be covered by bone?

- a. None;
- b. All;
- c. Three quarters;
- d. One fifth.