

Cite this article:

Popa ST, Popescu SM,
Constantinescu MV.
Occlusal equilibration
between option and clinical
reality.

Stoma Edu J. 2015;2(1):57-63

OCCLUSAL EQUILIBRATION BETWEEN OPTION AND CLINICAL REALTY

[https://doi.org/10.25241/stomaeduj.2015.2\(1\).art.6](https://doi.org/10.25241/stomaeduj.2015.2(1).art.6)

Sever Toma Popa^{1a},
Sanda Mihaela Popescu^{2b*},
Marian-Vladimir Constantinescu^{3c}

1. Department of Prosthetic Dentistry,
Faculty of Dentistry, "Iuliu Hatieganu" University
of Medicine and Pharmacy, Cluj-Napoca, Romania
2. Oral Rehabilitation Department, Faculty of Dental
Medicine, University of Medicine and Pharmacy
of Craiova, Craiova, Romania
3. Department of Prosthetic Dentistry,
Faculty of Dental Medicine, "Carol Davila" University
of Medicine and Pharmacy Bucharest,
Bucharest, Romania

a. DDS, PhD, Consultant Professor

b. MDM, PhD, Associate Professor

c. DDS, PhD, Professor

Abstract

Occlusal dysfunctions generated by occlusal interferences as part of occlusal pathology actually have growing frequency in oral pathology. Unfortunately because of their insidious appearance, they are unnoticed until injurious effects are observed or the patients experience dental, muscle or temporomandibular joint pains.

If occlusal interferences were observed at the beginning of their appearance, occlusal adjustments would rarely be necessary. To practice occlusal equilibration techniques the dentist needs to observe a number of accurate steps by step technical stages. These principles and stages are revealed in the following text.

Keywords: occlusal adjustment, occlusal equilibration, dental interferences, centric relation, deflective contacts.

Introduction

The mandibular neuromuscular complex has a strong adaptive capacity which allows functioning and protection of the masticatory system (Dawson, 1989, 2006). Deflective occlusal contacts will induce an irritable condition into the neuromuscular system which will be continuously reinforced with each closure through proprioceptive feedback. This conditioned state (engram) may induce changes at the level of any components of the masticatory system: teeth, muscles, periodontium, gingival mucosa and temporomandibular joints. Occlusal dysfunctions can be cured by using deprogramming methods (Popa S, 2004). One of the frequently used deprogramming techniques is occlusal equilibration (Wenneberg et al, 1988; Constantinescu, Ene, 1995) or selective grinding (Winstanley, 1986; Saito, 1990; Acosta, Roura, 2009). Occlusal equilibration is a therapeutical abrasive technique that can remove or correct occlusal interferences using the selective grinding of the cuspal slopes or ridges of the teeth interfered with normal functional occlusal paths. This method of correcting occlusion can be applied at the occlusal surface of natural teeth or prosthetic reconstructions using occlusal therapeutic grinding techniques. The best means to practice this method is to consider centric relation (CR) as the best

concept for the settlement, registration, transfer and reproducibility reference position of the mandible. This reasoning relies on the stability of the physiologic hinge axis position during relaxed and asymptomatic function of the elevator muscles of the mandible and the pain releasing of the temporomandibular joint dysfunction on patients to whom occlusal adjustments are to be made. The recording of precise and reproducible centric relation during mandibular condyles pure rotation around hinge terminal axis is the first step of a method claimed to provide a true and correct occlusal equilibration. Kerstein et al (1990, 1991, 1992, 1997, 2010) published another technique called immediate complete anterior guidance development (ICAGD). This computer-assisted technique aimed to obtain a successful reduction in disocclusion time, reducing contractile muscle activity and interrupting fatigue and spasm in masticatory muscles. Compared with classical occlusal equilibration, this technique let all jaw movements free and unguided by the operator and the sequence of adjustments were completely reversed as compared to that of traditional occlusal equilibration. All mandibular excursions were adjusted and immediate posterior disocclusion in all excursions was established before any habitual closure adjustments were done. Molar contact was decreased.

Received: 12 December 2013

Accepted: 16 November 2014

* Corresponding author:

Associate Professor Sanda Mihaela Popescu,
MDM, PhD
Faculty of Dental Medicine
University of Medicine and Pharmacy of Craiova
2.4. Petru Rares Str.
RO-200349 Craiova
Dolj, Romania.
Tel/Fax: +40251524442.
e-mail: sm_popescu@hotmail.com

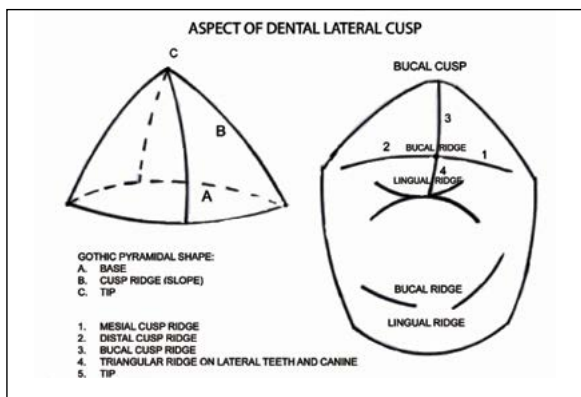


Figure 1. Gothic pyramidal aspect of a dental lateral cusp

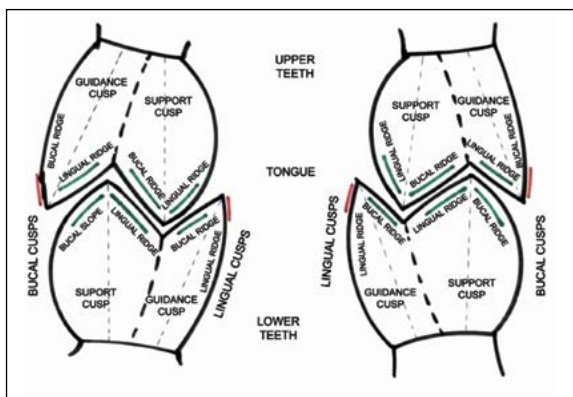


Figure 2. Occlusal slopes of maxillary and mandibular support cusps and guidance cusps

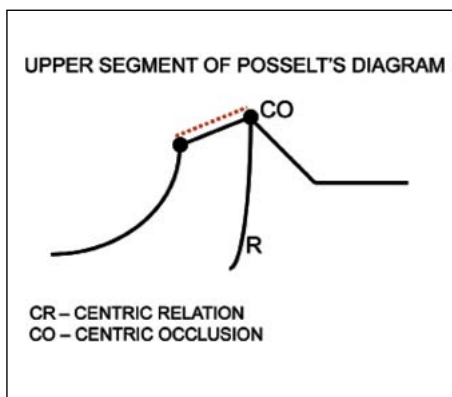


Figure 3. Distance between centric relation (CR) and centric occlusion (CO) on the upper segment of Posselt's diagram

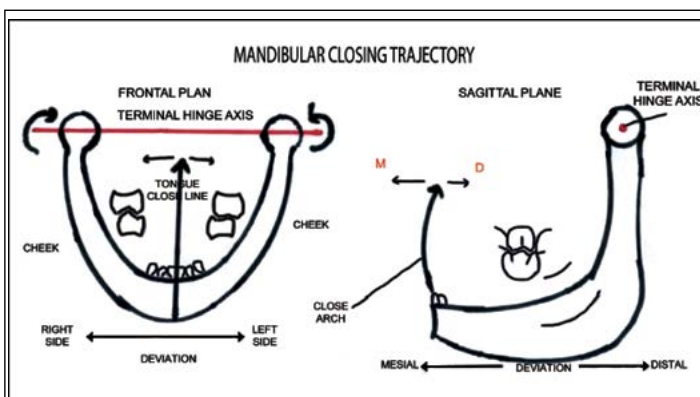


Figure 4-5. Mandibular closing trajectory (closing line) around hinge axis in frontal plane and the possible deviations towards the right or left side of the mandible. On sagittal closing trajectory (closing arch) around the hinge axis of the mandible it can be deviated towards the mesial or distal

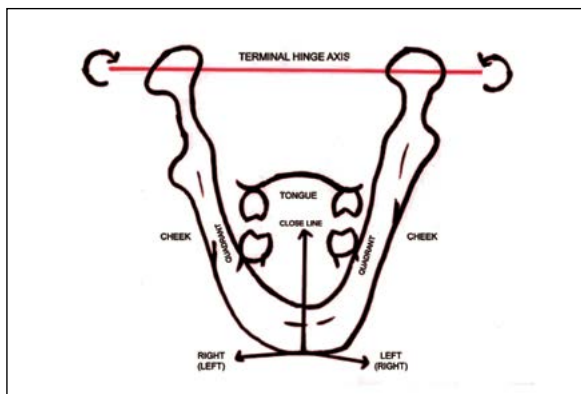


Figure 6. When the mandible on the close line (frontal plane) moves to the right side, its right quadrant moves to the cheek and the left quadrant moves to the tongue and vice versa

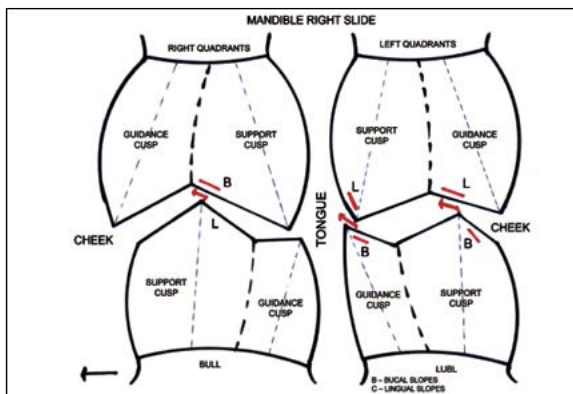


Figure 7. The occlusal interferences between the occlusal slopes of lateral teeth (red lines) which force the mandible to move towards the right side

Occlusal equilibration is indicated because it removes the disagreement and occlusal and temporomandibular joint dysfunctions of the TMJ-dysfunction syndrome. Fully functional maxillary and mandibular dental arches have the role to protect a harmonious occlusal function against parafunctional activity of neuromuscular system: pain around the temporomandibular joints or

the masticatory muscles with or without clicking, inability to fully open the mouth, head and neck aches (Torii, Chiwata, 2007). Factors such as the interocclusal distance envelope of mandibular motion, chewing stroke, tooth to tooth relations and determinants of occlusion can be improved by occlusal adjustments at the level of working or balancing quadrants.

OCCLUSION

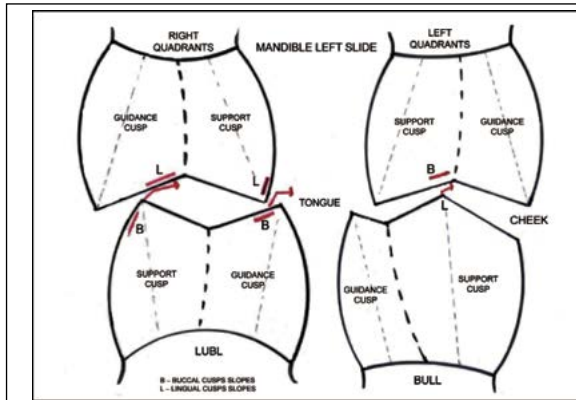


Figure 8. The interferences between the occlusal slopes of lateral teeth (red lines) which force the mandible to move towards the left side

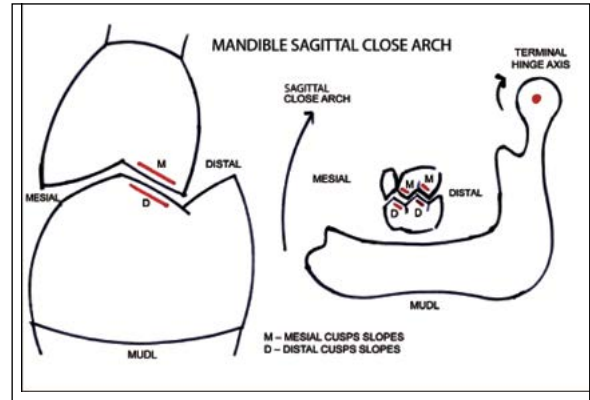


Figure 9. The interferences between occlusal slopes of lateral teeth (red lines) which force the mandible to move forward on the sagittal closing arch

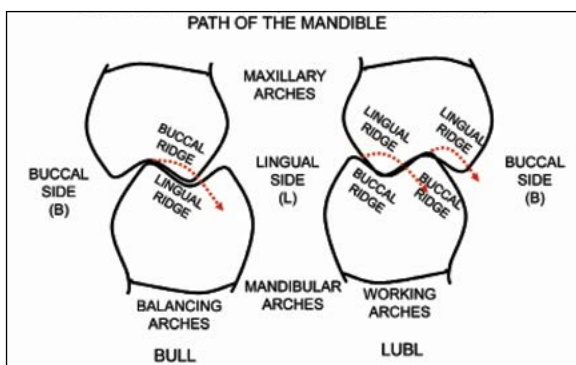


Figure 10. The slopes of lateral teeth to be reduced on balancing and working arches (red dotted lines) on the left laterotrusive path of the mandible

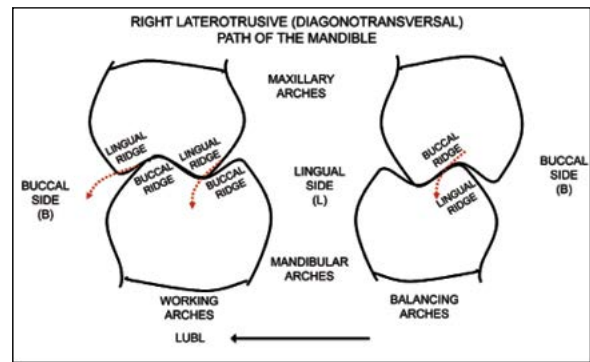


Figure 11. The slopes of lateral teeth to be reduced on the balancing and working arches (red dotted lines) on the left laterotrusive path of the mandible

An equilibrated occlusal function can be also achieved by dental prosthesis or orthodontic devices (Gupta et al, 2012). Occlusal adjustments techniques can be applied on natural teeth or on the teeth of fixed prostheses applied on the natural or implant abutments. The purpose of occlusal adjustments is to obtain a functional occlusion, not an ideal one. The ideal occlusion is not a practical functional occlusion; it is a theoretical, fictional one. The occlusal equilibration in the case of complete dentures is made somehow differently from the one made on natural dental arches. It is coordinated according to the Gysi's occlusal prosthetic concept: occlusal support on at least three points on all functional paths: right, left sideways and protrusive.

Objectives

- To improve the functional mandibulo-maxillary interrelations and of physiologic dento-periodontal stimuli.
- To remove occlusal trigger factors and muscle spasms joined with pain and functional discomfort.
- To remove the pain dysfunction TMJ syndrome, The steadiness of an equilibrated occlusal function before any prosthetic treatment,
- The used dental crowns can be contoured with a view to improve masticatory efficacy and periodontal

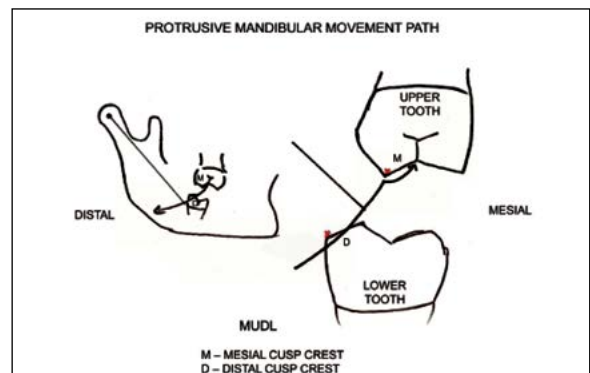


Figure 12. The cusps crests of the lateral teeth to be reduced (red points) on the protrusive movement path of the mandible

tissues protection,
-The stabilization of therapeutical results of orthodontic treatments.

The main targets of occlusal adjustments

- A. Primary occlusal trauma which affects odontal tissues: teeth and dental pulp, periodontium, temporomandibular joints, neuromuscular system, oral mucosa.
- B. Secondary occlusal trauma which affects physiological teeth mobility as well as hard and soft support tissues of the teeth.
- C. Generally occlusal adjustments are suggested to be made onto natural teeth before prosthetic treatments

with a view to not perpetuating occlusal cuspal incongruous slopes.

D. The limitation of the envelope of masticatory movements.

Elemental occlusal dental topography

The cusp slope of every tooth resembles a gothic pyramid: it has a base, ridges (slopes) and a tip (Fig. 1) Woelfel. An image of the teeth occlusal contacts between the ridges of the teeth in occlusal intercuspation is explanatory. Every maxillary and mandibular lateral tooth has buccal and lingual cusps. Every cusp has buccal and lingual ridges (slopes). Every ridge (slope) of the lateral teeth has occlusal contacts during masticatory movements (green color), except for the buccal ridges (slopes) of buccal guidance cusps of the maxillary teeth and lingual ridges (slopes) of lingual guidance cusps of mandibular teeth (red color). The buccal slopes of the guidance cusps of maxillary teeth and the lingual slopes of guidance cusps of mandibular teeth are rarely adjusted (Fig. 2).

Material and method

It is customary to use different diamond burs for occlusal adjustments: round-end tapered diamond, chamfer diamond, medium wheel diamond, round diamond burs, dura-white different size, white polishing stones of enamel, thin and extra thin articulating papers.

Occlusal equilibration using dental occlusal adjustment has some subsequent stages:

I. *The removal of all occlusal interferences on intercuspation path of mandible movement around hinge terminal axis (centric relation).* These occlusal interferences arise between CR and CO points on Posselt's diagram (Fig. 3).

The mandible closing into centric relation position must be examined into two plans: frontal (close line) and sagittal (close arch).

On the frontal close line, the direction of the mandible close to the centric relation can be deviated towards the left or right side because of occlusal interferences (Fig. 4). On the sagittal close arch the direction of the mandible close to the centric relation can be deviated towards the mesial or distal side because of occlusal interferences (Fig. 5). On the close line of the mandible into centric relation, when tooth interferences are present, one quadrant of the mandible slides towards the cheek and the opposite quadrant slides towards the tongue, irrespective of whether the mandible slides right or left (Fig. 6).

Thus, on the level of the teeth of the quadrant sliding towards the cheeks buccal ridges of maxillary support cusps, or lingual ridges of mandibular support cusps are ground: BULL.

On the level of the teeth of the quadrant sliding towards the tongue lingual ridges of maxillary and / or buccal ridges of the mandibular teeth are ground: LUBL (Fig. 2;7;8).

On the sagittal close arch in centric relation the mandible slides toward the mesial direction when

occlusal interferences are present. These mesial slides are not symmetrical (99% of the cases): usually they are mesiolaterotrusion, and symmetrical only in 1% of the cases. On the sagittal close arch, when the mandible slides towards the mesial, because of dental interferences, the mesial slopes of maxillary cusps of lateral teeth and distal slopes of mandibular cusps of lateral teeth must be ground: MUDL (Fig. 9). One rule of occlusal equilibration technique is that the slope of the cusp must be ground is that whose tip is nearer the central groove of antagonistic tooth.

II. *The removal of occlusal interferences on the laterotrusion (diagonotransversal) paths of the masticatory cycle.* The removal of occlusal interferences on the laterotrusion functionally paths is coordinated by the anterior (dental) and posterior (condylar) guidances of the mandible. The laterotrusion guidance is dependent on the individual masticatory cycle.

On the mandibular laterotrusion functionally paths interferences can appear at the working or balancing dental arches. As a rule the occlusal interferences of balancing arches are removed first. The mandible is guided alternatively, right and left from the centric relation position on the functionally masticatory paths with the purpose of occlusal interferences registration. At the level of balancing arches buccal ridges of maxillary (upper) lateral teeth or lingual ridges of mandibular (lower) lateral teeth are removed: BULL. At the working arches the lingual ridges of maxillary (upper) lateral teeth or the buccal ridges of mandibular (lower) lateral teeth are removed: LUBL (Fig. 10 and 11).

III. *The removal of occlusal interferences on the protrusive path of the masticatory cycle is done likewise.* These interferences can appear at the mesial slopes of cusps of maxillary (upper) teeth and/or distal slopes of cusps of mandibular (lower) teeth or at the level of the anterior (dental) guidance path on lingual surfaces of upper frontal teeth, or on labial surfaces of lower frontal teeth. They frequently deviate the protrusive trajectory direction of the mandible toward the left or right sides.

So, having as functional mark of mandible protrusive movement on posterior (condylar) and anterior (dental) guidance primary interferences must remove first. Usually, the primary interferences appears on the occlusal surfaces of lateral teeth hindering the smooth protrusive functional path of mandible. The technique of occlusal adjustment is to reduce interferences at the level of maxillary dental cusps mesial slopes (upper) and at the level of mandibular dental cusps distal slopes (lower), MUDL (fig. 12). At the level of frontal teeth (dental guidance) the technique is to reduce lingual surfaces (upper teeth) and labial surfaces (lower teeth). If it is necessary more adjustments, they can be repeated in the same manner.

Discussion

Subject to controversy, occlusal equilibration is a tickler. Excellent results obtained after selective

grinding in cases with temporomandibular disorders are reported Winstanley in 1986, Saito in 1990, McHorris in 1985 and many others. Conversely, according to Koh and Robinson (2003, 2004) clear evidence that occlusal adjustment treats or prevents temporomandibular disorders is lacking. Therefore there is a need for well designed controlled studies to analyze the current clinical practices and effectiveness. Occlusal equilibration is not an easy treatment because if it is not correctly conceived and performed, it will be more injurious than if it were not done. That is why there are some rules on how to carry it into practice:

1. The precise diagnosis and localization of occlusal interferences.
2. The identification of abrasion facetes on the dental cusps.
3. The verification on the casts mounted on semiadjustable articulators the occlusal interferences points registered in the patient's mouth.
4. A correct occlusal equilibration cannot be finalized during only one treatment seance.
5. Wrong centric relation position of the mandible compromises occlusal equilibration by occlusal adjustments.
6. The true centric relation of the mandible must be achieved having the mandibular condyles placed in their highest position in glenoide fosses, without occlusal teeth contacts
7. Real centric relation is not obtained by "forced

guidance" of the mandible but through mandibular muscles relaxation. Centric relation is a fibroligamentous connection between temporal glenoid fosse and mandibular condyles.

8. Occlusal equilibration outside the centric relation position of the mandible brings about occlusal dysfunction.

The iatrogenic errors during occlusal equilibration have different reasons: the wrong initial diagnosis, a wrong premise or indication of occlusal adjustment, the dentist's insufficient training in the field of occlusal adjustments and reduction of occlusal vertical dimension.

Conclusions

The masticatory system is a unitary functional biomechanical complex. Therefore, the homogenous functional dentoperiodontal impulses are highly significant with respect to the development and maintenance of dentoperiodontal, temporomandibular joints and masticatory muscles in soundness functional capacity and resistance.

Occlusal adjustment techniques offer a direct and easy opportunity in order to reach the equilibrium of occlusal interrelations, thanks to the perception of the homogenous functional stimuli. In this way, the occlusal surfaces of the teeth are liable to a uniform, smooth physiological abrasion process.

Bibliography

1. Dawson PE. Evaluation, Diagnosis and Treatment of Occlusal Problems. 2nd ed. St. Louis: The C.V. Mosby Co. 1989; 41-62.
2. Dawson PE. Functional Occlusion: From TMJ to Smile Design, St. Louis: Mosby Elsevier; 2007
3. Popa S. Ocluzia dentară normală, patologică și terapeutică. Cluj-Napoca: Ed. Dacia, 2004; 284-293
4. Wenneberg B, Nyström T, Carlsson GE. Occlusal equilibration and other stomatognathic treatment in patients with mandibular dysfunction and headache. *J Prosthet Dent.* 1988;59(4):478-83.
5. Constantinescu MV, Ene L. Echilibrarea ocluzală prin șlefuire selectivă progresivă a dinților naturali cu ajutorul separatorului ocluzal. *Stomatologia (Buc)* 1995;XXII(3-4):111-116.
6. Winstanley RB. A retrospective analysis of the treatment of occlusal disharmony by selective grinding. *J Oral Rehabil.* 1986;13(2):169-181.
7. Saito T. Occlusal adjustment by selective grinding and use of an anterior deprogrammer. *Quintessence Int.* 1990;21(11):887-892.
8. Acosta R, Roura N. A review of the literature on the causal relationship between occlusal factors (OF) and temporomandibular disorders (TMD) IV: experimental studies of occlusal adjustment by selective grinding as a preventive or therapeutic intervention. *Rev Fac Odontol Univ Antioq.* 2009;21(1):98-111.
9. Kerstein RB, Farrell S. Treatment of myofascial pain-dysfunction syndrome with occlusal equilibration. *J Prosthet Dent.* 1990;63(6):695-700.
10. Kerstein RB, Wright NR. Electromyographic and computer analysis of patients suffering from chronic myofascial pain-dysfunction syndrome: before and after treatment with immediate complete anterior guidance development. *J Prosthet Dent.* 1991;66(5):677-686.
11. Kerstein RB. Disocclusion time-reduction therapy with immediate

complete anterior guidance development to treat chronic myofascial pain-dysfunction syndrome. *Quintessence Int.* 1992;23(11):735-747.

12. Kerstein RB, Chapman R, Klein M. A comparison of ICAGD (immediate complete anterior guidance development) to mock ICAGD for symptom reductions in chronic myofascial pain dysfunction patients. *Cranio.* 1997;15(1):21-37.

13. Kerstein RB. Reducing chronic masseter and temporalis muscular hyperactivity with computer-guided occlusal adjustments. *Compend Contin Educ Dent.* 2010;31(7):530-534, 536, 538 passim.

14. Torii K, Chiwata I. Occlusal management for a patient with aural symptoms of unknown etiology: a case report. *J Med Case Rep.* 2007;1:85.

15. Gupta ND, Maheshwari S, Prabhat KC, Goyal L. A critical review of the management of deep overbite complicated by periodontal diseases. *Eur J Gen Dent.* 2012;1(1):2-5.

16. Mc Horris WH. Occlusal Adjustment via Selective Cutting of Natural Teeth. Part I. *Int J Periodontics Restorative Dent.* 1985;5(5):8-25.

17. McHorris WH. Occlusal Adjustment via Selective Cutting of Natural Teeth. Part II. *Int J Periodontics Restorative Dent.* 1985;5(6):8-29.

18. Koh H, Robinson PG. Occlusal adjustment for treating and preventing temporomandibular joint disorders. *Cochrane Database Syst Rev.* 2003;(1):CD003812.

19. Koh H, Robinson PG. Occlusal adjustment for treating and preventing temporomandibular joint disorders. *J Oral Rehabil.* 2004;31(4):287-292.

20. Rickne C, Scheid. WOELFEL'S Dental Anatomy. It's Relevance to Dentistry. 7th ed. Phla.: Wolt. Kluw and Lippincott Williams & Wilkins Co., 2007;120

Sever Toma Popa

Professor Consultant, DDS, PhD, Department of Prosthetic Dentistry, Faculty of Dental Medicine, "Iuliu Hateganu" University of Medicine and Pharmacy Cluj-Napoca, Romania



CV

In 1963 - graduated from Faculty of Dentistry Cluj (DDS). PhD title in 1972. Specialized in Dental Prosthetics and Occlusion. Training: New York State University (1981); University of Florida; Ohio State University, USA. Member of New York Academy of Science, Romanian Medical Association (1964), Union Medical Balcanique (1977), European Prosthodontics Association (EPA) London (1993), International College of Prosthodontics, San Diego, California (2003) and Romanian Journal of Stomatology Editorial Board. Research fields: Animal traumatic occlusion - experimental model in study of occlusion and periodontal trauma; Clinical studies of TMJ Dysfunction syndrome; Periimplant modification under occlusion load; Maxillo-mandibular relationship; Treatment methods in occlusion pathology. Interested in Pathology of partial edentoulism, and Occlusion disorders and Fixed dental prostheses. He has author of more then 80 publications and personal communications, and 5 books.

Questions

The frequency of occlusal dysfunctions generated by occlusal interferences is...?

- a. declining
- b. steady;
- c. declining fast;
- d. growing.

The patient with occlusal dysfunctions can have...?

- a. only dental pains;
- b. only muscle pains;
- c. only temporomandibular joints pains;
- d. dental, muscle or temporomandibular joints pains.

How often would occlusal adjustments be necessary if occlusal interferences were observed when they appear?

- a. never;
- b. always;
- c. rarely necessary;
- d. always necessary.

Which is not used for occlusal adjustments?

- a. round-end tapered diamond;
- b. chamfer diamond;
- c. square-end tapered diamond;
- d. medium wheel diamond.