

## EVALUATION OF UPPER ARCH CHANGES IN PATIENTS WITH UNILATERAL CLEFT LIP AND PALATE AFTER MAXILLARY EXPANSION USING DIGITAL DENTAL CASTS

Fabrizia d'Apuzzo<sup>1a</sup> , Ludovica Nucci<sup>1b</sup> , Abdolreza Jamilian<sup>2c</sup> , Rosario Rullo<sup>1d</sup> , Vincenzo Grassia<sup>1e</sup> , Letizia Perillo<sup>1f\*</sup> 

<sup>1</sup>Multidisciplinary Department of Medical-Surgical and Dental Specialties, University of Campania Luigi Vanvitelli, Naples, Italy

<sup>2</sup>Department of Orthodontics, Islamic Azad University, Tehran, Iran

<sup>a</sup> DDS, MS, PhD, Research fellow; e-mail: fabriziadapuzzo@gmail.com; ORCIDiD: <https://orcid.org/0000-0003-0291-9339>

<sup>b</sup> DDS, PhD student; e-mail: ludortho@gmail.com; ORCIDiD: <https://orcid.org/0000-0002-7174-7596>


<sup>c</sup> DDS, MSc, OMFS, Full professor; e-mail: info@jamilian.net; ORCIDiD: <https://orcid.org/0000-0002-8841-0447>

<sup>d</sup> MD, MS, Associate professor; e-mail: rosario.rullo@unicampania.it; ORCIDiD: <https://orcid.org/0000-0002-5418-8171>

<sup>e</sup> DDS, MS, PhD, Lecturer; e-mail: grassiavincenzo@libero.it; ORCIDiD: <https://orcid.org/0000-0002-6671-2380>

<sup>f</sup> MD, MS, PhD, Professor, Head, Dean; e-mail: letizia.perillo@unicampania.it; ORCIDiD: <https://orcid.org/0000-0001-6175-7363>

### ABSTRACT

 [https://doi.org/10.25241/stomaedu.2020.7\(3\).art.4](https://doi.org/10.25241/stomaedu.2020.7(3).art.4)

**Objective** To compare the upper arch dimensions of young patients with unilateral cleft lip and palate (UCLP) before and after treatment with bonded maxillary expander and hybrid activation protocol using digital dental casts.

**Methods** Sixteen subjects with UCLP, aged between 7 and 14 years (mean age 10.9 ± 2.7 years) consecutively treated with bonded maxillary expander and hybrid activation were included. The dental casts before and after treatment were digitalized using a 3Shape scanner. Intercanine, interpremolar and intermolar widths (at cusp and gingival levels) and arch perimeters were measured. The significance level for statistical analyses was set as p < 0.05.

**Results** The total treatment time using the hybrid expansion protocol lasted 12 ± 1.9 months while the active expansion time lasted 4 ± 0.2 months. Patients with UCLP showed significant differences in all transverse upper arch dimensions both at cusp and gingival level.

**Conclusion** The use of a bonded maxillary expander with a hybrid activation protocol during growth may be efficient to improve all transverse upper arch widths in patients affected by UCLP.

### KEYWORDS

Cleft Lip and Palate; Maxillary Expansion; Bonded Expander; Hybrid Expansion Protocol; Digital Dental Casts.

### 1. INTRODUCTION

Cleft Lip and Palate (CLP) is one of the most common types of congenital craniofacial birth anomalies due to environmental, genetic and epigenetic risk factors interacting among them [1-3].

They can occur between the fourth and twelfth week of gestation due to the failure of fusion between the medial nasal and maxillary processes in the primary palate or the palatal units in the secondary palate [4]. Affected patients need interdisciplinary care since birth until adulthood and evince higher

morbidity and mortality throughout life compared to noncleft subjects [5]. Oral rehabilitations usually require complex and challenging interdisciplinary treatments since the first post-birth weeks do not allow the most adequate early recovery of vital functions [5,6].

Craniofacial growth harmony in patients with unilateral or bilateral CLP is affected in all 3 dimensions (3D). Previous studies showed that it can be only partially improved after surgery during childhood [7-9]. Lip surgery is usually performed at 6 months of age using the Delaire technique, soft

 **OPEN ACCESS** This is an Open Access article under the CC BY-NC 4.0 license.

**Peer-Reviewed Article**

**Citation:** d'Apuzzo F, Nucci L, Jamilian A, Rullo R, Grassia V, Perillo L., Evaluation of upper arch changes in patients with unilateral cleft lip and palate after maxillary expansion using digital dental casts. *Stoma Edu J.* 2020;7(3):184-190.

**Received:** May 29, 2020; **Revised:** June 05, 2020; **Accepted:** June 07, 2020; **Published:** June 09, 2020

**\*Corresponding author:** Prof. Letizia Perillo; Multidisciplinary Department of Medical-Surgical and Dental Specialties, University of Campania Luigi Vanvitelli, via L. De Crecchio 6, 80138 Naples, Italy  
 Tel./Fax: +39 3334027273; e-mail: letizia.perillo@unicampania.it

**Copyright:** © 2020 the Editorial Council for the Stomatology Edu Journal.

**Table 1.** Age, treatment time and sex ratio of the UCLP patients.

Variable	Mean	SD
Initial age (years)	10,9	2,7
Total Treatment time (months)	12,0	1,9
Active Treatment time (months)	4,0	0,2
Sex		
Female	10	
Male	6	

**Table 2.** Random and systematic errors of the measurements performed on the digital dental models.

Measurements	T0		T1	
	D Dahlberg	Systematic error P level	D Dahlberg	Systematic error P level
3-3 cusp	1.30	NS	1.55	NS
3-3 gingival	1.24	NS	0.78	NS
4-4 cusp	0,89	NS	1.56	NS
4-4 gingival	1.50	NS	1.34	NS
5-5 cusp	1.45	NS	2,01	NS
5-5 gingival	1.67	NS	1.34	NS
6-6 cusp	1.07	NS	1.67	NS
6-6 gingival	0.98	NS	0.87	NS
AP	4.06	NS	1.81	NS

\* $p < 0.05$ , \*\* $p < 0.005$

palate surgery at 12 months and hard palate surgery at 18 months, whereas secondary alveolar bone graft is usually planned when the patient is around 9 to 12 years old [10-12]. When the surgical protocol for the hard palate closure is delayed, the occlusion is even more affected [12].

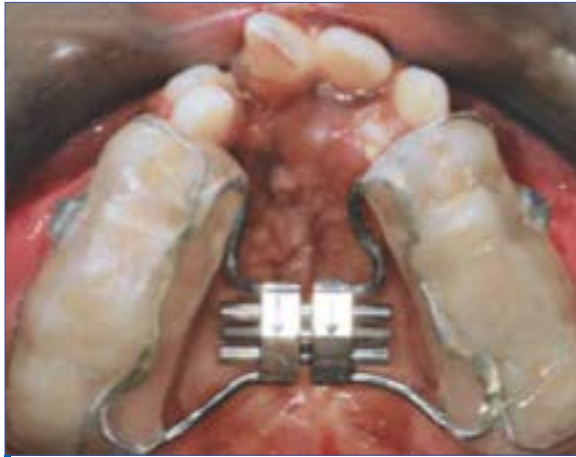During the early mixed dentition, the maxillary arch linear dimensions significantly differ between the unilateral cleft lip and palate (UCLP) group and the noncleft group, [13] while the intercanine width seems to be more reduced in bilateral complete clefts due to scars resulting from palatal surgery [14]. It has been also demonstrated that children with UCLP usually suffer from a nasomaxillary complex deficiency which continues worsening until the end of their growth and have maxillary dental arches constricted in width and length [15].

Thus, it is suggested to ideally start to perform an early dentofacial orthopedic treatment protocol during the mixed dentition [16]. In the light of these findings, an interceptive treatment with a palatal expander is usually proposed as a first approach [17-19]. The palatal expander allows to correct transverse skeletal maxillary constriction and dental posterior crossbite [20]. There are several different maxillary expansion modalities based on the appliance design [21] or the type of activation and no differences were found between slow or rapid expansion protocols in children with bilateral CLP [17,22]. Thus, the positive effects on the occlusion are undeniable in patients with CLP modifying the upper arch diameters and stimulating the transversal skeletal growth, even without leading to the same amount of bone

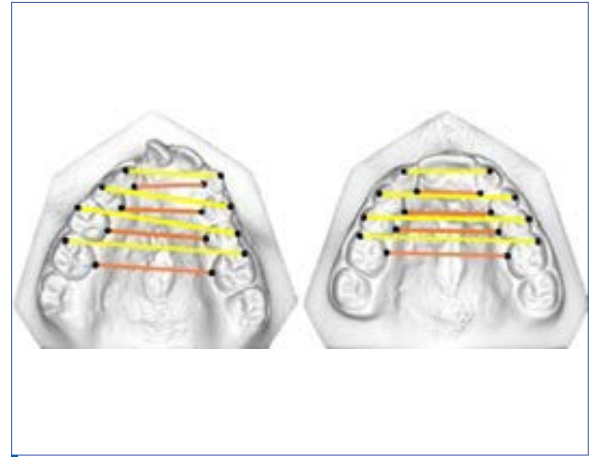
formation, as reported in normal patients [23]. However, to the best of our knowledge, there are no studies treating subjects affected by CLP using a bonded maxillary expander with a hybrid activation [24-27]. The bonded expander seems to have some advantages such as better control of vertical growth, reduced interocclusal interferences and less dental tipping due to acrylic splints covering both occlusal, buccal and palatal surfaces of teeth [28-30]. Many papers conducted the palatal analysis of patients with CLP as compared to controls using novel three-dimensional (3D) technologies [31-33]. Nowadays, the use of digital models is considered useful for treatment planning and outcome evaluations and the reliability of measurements from 3D dental casts as compared to those obtained directly from plaster models is evidence-based [34]. Thus, the purpose of this study was to evaluate upper arch dimensions on digital dental casts in young patients with UCLP before and after treatment using a bonded maxillary expander with a hybrid activation.

## 2. METHODOLOGY

This retrospective observational study was based on the analysis of data collected from patients with UCLP who had completed an orthodontic treatment with maxillary expansion at the Orthodontic Program of the University of Campania Luigi Vanvitelli, Naples, Italy. The research was carried out in accordance with the Declaration of Helsinki and approved by the ethics committee of the University of Campania Luigi Vanvitelli, Naples, Italy (Prot. N°147). An



**Figure 1.** Intraoral photograph of bonded maxillary expander in a patient with UCLP.



**Figure 2.** Assessment on the digital model of arch widths: at the cusp (yellow lines) and gingival (orange lines) level.

informed consent was obtained from the parents of each patient. Here are the inclusion criteria: patients affected by UCLP, age ranging between 7 and 14 years, constricted upper arch, cervical vertebral maturation between CS1 and CS4 and treatment protocol including a bonded maxillary expander with hybrid activation [24,26]. Subjects with other craniofacial syndromes, previous orthodontic treatment or incomplete documentation were excluded.

All patients had been previously treated at the Division of Maxillofacial Surgery at the University of Campania Luigi Vanvitelli, Naples, Italy, by the same surgeon, using the same protocol and method as follows: lip surgery at 6 months, soft palate surgery at 12 months and hard palate surgery at 18 months. No infant orthopaedics was carried out prior to surgery. The initial (T0) and after expansion (T1) plaster models of each patient were collected to be digitalized and then analyzed [35].

The treatment was performed with a bonded palatal expander (Fig.1) [16] applied on the upper lateral teeth. The activation started after the appliance onset and ended when overcorrection was achieved. The protocol used had two phases: the initial phase started at the chair side and included three steps with four, two and one turn, respectively; the second one followed at home with one turn every 3 days [24, 26]. During the active expansion phase depending on the degree of maxillary constriction, the patients were monitored every 2 weeks.

After the active expansion phase, the screw of the appliance was closed with acrylic composite and the expander was used as a retainer for about 8 months. The expander was removed after about 1 year and a second plaster model was realized. Both dental casts were scanned using the 3shape TRIOS<sup>®</sup>, with a reported manufacturing accuracy of less than 20 microns (www.3shape.com), by the same trained operators. The digital models were exported in STL surface mesh then imported in Viewbox 4 (dHal Software, Kifissia, Greece). A total of nine linear measurements of the upper dental

arch were considered: transverse intercanine (3-3), interpremolar or interdeciduous molar (4-4 and 5-5) and intermolar (6-6) distances at both cusp tips and gingival levels, and arch perimeter (AP) calculated as circumference of the dental arch, measured from the distal surface of the maxillary permanent first molars on the right side to the distal surface of the contralateral ones.

### 2.1. Statistical analysis

The reliability of the measurements was determined by randomly selecting five dental casts before and after the expansion treatment. They were measured twice after a two-week interval. Dahlberg's formula was used to quantify the measurement error. An Intraclass Correlation Coefficient was also calculated to assess test/retest reliability. An unpaired t-test and a Wilcoxon signed-rank test were utilized to evaluate any significant difference before and after treatment. The statistical significance was set at  $p < 0.05$ .

All statistical analyses were performed with SPSS software (Statistical Package for the Social Sciences, SPSS, Version 12, Chicago, IL, USA).

## 3. RESULTS

The total sample included 16 patients, 10 females and 6 males. The initial mean age was  $10.9 \pm 2.7$  years. The total treatment phase with the bonded expander (T0-T1) lasted  $12.0 \pm 1.9$  months while the active expansion phase was  $4.0 \pm 0.2$  months (Table 1). The statistical analysis confirmed that there were no systematic measurement errors before and after treatment, as shown in (Table 2).

Comparing measurements at T0 and T1 showed statistically significant differences in all transverse arch widths while arch perimeter values revealed no differences (Table 3).

As to the difference arch diameters at both cusp tips and gingival levels (Table 4), data showed statistically significant differences only for the diameter 3-3 measured at cusp level.

**Table 3.** Measurements before (T0) and after maxillary expansion (T1).

Variable	T0 mean value (mm)	T1 mean value (mm)	STD Error	t	S
3-3 cusp	26,72	31,36	1,59	0,01*	0,01*
3-3 gingival	21,72	24,81	1,38	0,04*	0,04*
4-4 cusp	34,18	40,05	1,73	0,004**	0,006*
4-4 gingival	23,08	28,43	1,51	0,003**	0,007*
5-5 cusp	40,68	46,40	1,92	0,009*	0,01*
5-5 gingival	26,94	33,16	1,82	0,004**	0,005**
6-6 cusp	49,90	55,79	1,65	0,003**	0,002*
6-6 gingival	32,76	38,65	1,55	0,002**	0,003**
AP	88,76	88,41	3,18	0,91	0,61

\* $p < 0.05$ , \*\* $p < 0.005$ **Table 4.** Mean differences between measurements at the cusp and gingival level of arch widths, before and after maxillary expansion.

Variable	Mean difference T1-T0 (mm)	STD Error	t	S
3-3	- 1,54	0,41	0,002**	0,004**
4-4	- 0,52	0,48	0,29	0,53
5-5	0,50	0,59	0,41	0,77
6-6	0,00	0,39	0,98	0,95

\* $p < 0.05$ , \*\* $p < 0.005$ 

#### 4. DISCUSSION

Several previous studies showed significant different maxillary morphologies in patients with CLP in mixed or permanent dentition when compared to matched controls before any orthopedic/orthodontic treatment [31-33,36]. In particular, the upper intercanine widths significantly decreased both at cusp and gingival levels [13-15,37]. Therefore, there is a complete agreement on the need to expand the maxillary arch in patients affected by CLP. The reasons to use an expander in the orthodontic treatment plan are manifold. Iwasaki et al. [38] found that the nasal airway flow significantly improved after rapid maxillary expansion in patients with UCLP increasing both the quantity of airflow and nasal cross-sectional area on the cleft side. Also, speech and deglutition enhance after expansion due to wider space for the tongue, [6,33] but, above all, the occlusal relationships result improved by widening the palatal dimensions [18].

Many investigations focused on dental and alveolar changes in patients with BCL and UCLP using different appliances and protocols. Our results have shed light on a different expansion appliance and protocol in patients with UCLP. Pugliese et al. [21] found that the maxillary expansion with Hyrax, Quad-helix and Expander with Differential Opening (EDO), in bilateral CLP patients, had similar changes in arch size, whereas only Quad-helix expander and EDO were associated with a greater shape at the intercanine area. Other researchers, comparing

slow and rapid activation through Quad-helix and Hyrax expanders, respectively, in children with bilateral CLP, showed differences only with respect to the treatment time. Specifically, the expansion active phase ranged from 4 to 21 months in the slow protocol and from 7 to 14 days in the rapid one [17,22]. Façanha et al. [20] assessing the effects achieved with the Haas and Hyrax expanders using a rapid protocol in patients with UCLP, highlighted similar increases of the transverse dimensions. Ayub et al. [39] performing the expansion with a rapid protocol, found significant increases of all maxillary measurements including arch perimeter probably due to the sample selection based on patients with a posterior crossbite. Conversely, in our study, this parameter did not change significantly. However, a direct comparison of our findings with other studies was only partially possible due to the differences in cleft features and size, patients' age, dentition period, expansion appliance and protocol as well as the data analyses performed. Nevertheless, our treatment outcomes may add a missing piece in the puzzle about maxillary arch changes after expansion treatment, underlying the possibility to achieve similar effects in a reduced time with a different type of expander and activation [16,24-26]. Our results confirmed the need for orthodontic treatment during the development of the permanent dental occlusion and showed increases in all transverse upper arch dimensions. Moreover, the bonded expander seemed to exert a more homogeneous lateral pressure on the two halves of the maxilla avoiding any possible interference of the lower arch due to the smooth acrylic splints covering the occlusal surface. Thus, the bonded expander along with the hybrid activation protocol should be suggested in UCLP as a procedure to achieve an efficient maxillary expansion with arch widths homogeneous increase avoiding buccal tipping of premolars and molars maintaining an adequate active treatment time, of about 4 months, in the middle between the slow and rapid protocol [17,22]. This investigation, of course, had some limitations such as the retrospective nature of the study design

with short-term outcomes, currently lacking long-term data [23]. Moreover, some subjects with UCLP had some permanent teeth missing in the dental arch on one or both sides.

The elimination of these patients, however, may have introduced higher selection bias eliminating more severely affected subjects with smaller arch widths which is actually a common clinical frame of CLP anomalies.

Future studies should be planned with an increased sample size, even to compare, with multicentric randomized clinical trials, this novel approach with the other conventional maxillary expansion protocol in patients with UCLP.

## 5. CONCLUSION

Growing patients with UCLP showed significant differences in all transverse upper arch dimensions after orthodontic treatment with a bonded maxillary expander and a hybrid activation protocol.

## REFERENCES

- Courbon MT. The complex genetics of cleft lip and palate. *Eur J Orthod.* 2004;26(1):7-16. doi: 10.1093/ejo/26.1.7. [\[Full text link\]](#)[\[CrossRef\]](#)[\[PubMed\]](#)[\[Google Scholar\]](#)[\[Scopus\]](#)
- Grassia V, Lombardi A, Kawasaki H, et al. Salivary microRNAs as new molecular markers in cleft lip and palate: a new frontier in molecular medicine. *Oncotarget.* 2018;9(27):18929-18938. doi:10.18632/oncotarget.24838. [\[Full text link\]](#)[\[CrossRef\]](#)[\[PubMed\]](#)[\[Google Scholar\]](#)[\[Scopus\]](#)
- Zhao J, Zhang B, Yang S, et al. Maternal exposure to ambient air pollutant and risk of oral clefts in Wuhan, China. *Environ Pollut.* 2018;238:624-630. doi:10.1016/j.envpol.2018.03.053. [\[Full text link\]](#)[\[CrossRef\]](#)[\[PubMed\]](#)[\[Google Scholar\]](#)[\[Scopus\]](#)[\[WoS\]](#)
- Mossey PA, Little J, Munger RG, et al. Cleft lip and palate. *Lancet.* 2009;374(9703):1773-1785. doi: 10.1016/S0140-6736(09)60695-4. [\[Full text link\]](#)[\[CrossRef\]](#)[\[PubMed\]](#)[\[Google Scholar\]](#)[\[Scopus\]](#)
- Rullo R, Festa VM, Rullo R, et al. Prevalence of dental anomalies in children with cleft lip and unilateral and bilateral cleft lip and palate. *Eur J Paediatr Dent.* 2015;16(3):229-232. [\[Full text link\]](#)[\[PubMed\]](#)[\[Google Scholar\]](#)[\[Scopus\]](#)[\[WoS\]](#)
- Rullo R, Di Maggio D, Addabbo F, et al. Speech outcome in unilateral complete cleft lip and palate patients: a descriptive study. *Eur J Paediatr Dent.* 2014;15(3):293-296. [\[Full text link\]](#)[\[PubMed\]](#)[\[Google Scholar\]](#)[\[Scopus\]](#)[\[WoS\]](#)
- Fudalej PS, Urbanova W, Klimova I, et al. The Slavcleft: a three-center study of the outcome of treatment of cleft lip and palate. Part 2: dental arch relationships. *J Craniomaxillofac Surg.* 2019;47(7):1092-1095. doi: 10.1016/j.jcms.2019.03.023. [\[Full text link\]](#)[\[CrossRef\]](#)[\[PubMed\]](#)[\[Google Scholar\]](#)[\[Scopus\]](#)
- Heliövaara A, Skaare P, Küssel A, et al. Scandcleft randomized trials of primary surgery for unilateral cleft lip and palate. Dental arch relationships in 8 year-olds. *Eur J Orthod.* 2020;42(1):1-7. doi: 10.1093/ejo/cjz067. [\[Full text link\]](#)[\[CrossRef\]](#)[\[PubMed\]](#)[\[Google Scholar\]](#)[\[Scopus\]](#)
- Küssel A, Mølsted K, Marcusson A, et al. Scandcleft randomized trials of primary surgery for unilateral cleft lip and palate: maxillary growth at eight years of age. *Eur J Orthod.* 2020;42(1):24-29. doi: 10.1093/ejo/cjz078. [\[Full text link\]](#)[\[CrossRef\]](#)[\[PubMed\]](#)[\[Google Scholar\]](#)[\[Scopus\]](#)
- Scalzone A, Flores-Mir C, Carozza D, et al. Secondary alveolar bone grafting using autologous versus alloplastic material in the treatment of cleft lip and palate patients: systematic review and meta-analysis. *Prog Orthod.* 2019;20(1):6. doi: 10.1186/s40510-018-0252-y. [\[Full text link\]](#)[\[CrossRef\]](#)[\[PubMed\]](#)[\[Google Scholar\]](#)[\[Scopus\]](#)
- Yang CJ, Pan XG, Qian YF, Wang GM. Impact of rapid maxillary expansion in unilateral cleft lip and palate patients after secondary alveolar bone grafting: review and case report. *Oral Surg Oral Med Oral Pathol Oral Radiol.* 2012;114(1):e25-e30. doi: 10.1016/j.oro.2011.08.030. [\[Full text link\]](#)[\[CrossRef\]](#)[\[PubMed\]](#)[\[Google Scholar\]](#)[\[Scopus\]](#)[\[WoS\]](#)
- Botticelli S, Küssel A, Marcusson A, et al. Do infant cleft dimensions have an influence on occlusal relations? A subgroup analysis within an RCT of primary surgery in patients with unilateral cleft lip and palate. *Cleft Palate Craniofac J.* 2020;57(3):378-388. doi: 10.1177/1055665619875320. [\[Full text link\]](#)[\[CrossRef\]](#)[\[PubMed\]](#)[\[Google Scholar\]](#)[\[Scopus\]](#)
- Garrahy A, Millett DT, Ayoub AF. Early assessment of dental arch development in repaired unilateral cleft lip and unilateral cleft lip and palate versus controls. *Cleft Palate Craniofac J.* 2005;42(4):385-391. doi:10.1597/03-159.1. [\[Full text link\]](#)[\[CrossRef\]](#)[\[PubMed\]](#)[\[Google Scholar\]](#)[\[Scopus\]](#)
- Loomans N, Decombel O, Goethals K, Mommaerts MY. Transverse maxillary development in complete cleft patients: comparison of 2 treatment strategies by longitudinal and cross-sectional model analysis. *Cleft Palate Craniofac J.* 2019;56(5):610-618. doi: 10.1177/1055665618802539. [\[Full text link\]](#)[\[CrossRef\]](#)[\[PubMed\]](#)[\[Google Scholar\]](#)[\[Scopus\]](#)
- Gopinath VK, Samsudin AR, Mohd Noor SNF, Mohamed Sharab HY. Facial profile and maxillary arch dimensions in unilateral cleft lip and palate children in the mixed dentition stage. *Eur J Dent.* 2017;11(1):76-82. doi: 10.4103/ejd.ejd\_238\_16. [\[Full text link\]](#)[\[CrossRef\]](#)[\[PubMed\]](#)[\[Google Scholar\]](#)[\[Scopus\]](#)
- Perillo L, Vitale M, d'Apuzzo F, et al. Interdisciplinary approach for a patient with unilateral cleft lip and palate. *Am J Orthod Dentofacial Orthop.* 2018;153(6):883-894. doi: 10.1016/j.ajodo.2016.12.035. [\[Full text link\]](#)[\[CrossRef\]](#)[\[PubMed\]](#)[\[Google Scholar\]](#)[\[Scopus\]](#)
- de Medeiros Alves AC, Garib DG, Janson G, et al. Analysis of the dentoalveolar effects of slow and rapid maxillary expansion in complete bilateral cleft lip and palate patients: a randomized clinical trial. *Clin Oral Investig.* 2016;20(7):1837-1847. doi: 10.1007/s00784-015-1675-1. [\[Full text link\]](#)[\[CrossRef\]](#)[\[PubMed\]](#)[\[Google Scholar\]](#)[\[Scopus\]](#)[\[WoS\]](#)
- Pan X, Qian Y, Yu J, et al. Biomechanical effects of rapid palatal expansion on the craniofacial skeleton with cleft palate: a three-dimensional finite element analysis. *Cleft Palate Craniofac J.* 2007;44(2):149-154. doi: 10.1597/05-161.1. [\[Full text link\]](#)[\[CrossRef\]](#)[\[PubMed\]](#)[\[Google Scholar\]](#)[\[Scopus\]](#)

## CONFLICT OF INTEREST

The authors declare no conflict of interest.

## AUTHOR CONTRIBUTIONS

Made substantial contributions to conception and design of the study and performed data analysis and interpretation: FdA, VG, LP. Performed data acquisition, as well as provided administrative, technical, and material support: LN, AJ, RR.

## FINANCIAL SUPPORT AND SPONSORSHIP

None.

## ETHICAL APPROVAL AND CONSENT TO PARTICIPATE

Research was performed in accordance with the Declaration of Helsinki and approved by the ethics committee of the University of Campania Luigi Vanvitelli, Naples, Italy (Prot. N° 147).

An informed consent to participate in the study was obtained.

## CONSENT FOR PUBLICATION

A written informed consent for publication was obtained.

19. Bejdová S, Krajiček V, Peterka M, et al. Variability in palatal shape and size in patients with bilateral complete cleft lip and palate assessed using dense surface model construction and 3D geometric morphometrics. *J Craniomaxillofac Surg.* 2012;40(3):201-208. doi: 10.1016/j.jcms.2011.04.013. [Full text link][CrossRef][PubMed][Google Scholar][Scopus]
20. Façanha AJ, Lara TS, Garib DG, da Silva Filho OG. Transverse effect of Haas and Hyrax appliances on the upper dental arch in patients with unilateral complete cleft lip and palate: a comparative study. *Dental Press J Orthod.* 2014;19(2):39-45. doi: 10.1590/2176-9451.19.2.039-045.oar. [Full text link][CrossRef][PubMed][Google Scholar][Scopus]
21. Pugliese F, Palomo JM, Calil LR, et al. Dental arch size and shape after maxillary expansion in bilateral complete cleft palate: a comparison of three expander designs. *Angle Orthod.* 2020;90(2):233-238. doi: 10.2319/020219-74.1. [Full text link][CrossRef][PubMed][Google Scholar][Scopus]
22. de Almeida AM, Ozawa TO, Alves ACM, et al. Slow versus rapid maxillary expansion in bilateral cleft lip and palate: a CBCT randomized clinical trial. *Clin Oral Investig.* 2017;21(5):1789-1799. doi: 10.1007/s00784-016-1943-8. [Full text link][CrossRef][PubMed][Google Scholar][Scopus] [WoS]
23. Al-Gunaid T, Asahito T, Yamaki M, et al. Relapse tendency in maxillary arch width in unilateral cleft lip and palate patients with different maxillary arch forms. *Cleft Palate Craniofac J.* 2008;45(3):278-283. doi: 10.1597/07-053. [Full text link][CrossRef][PubMed][Google Scholar][Scopus]
24. Grassia V, D'Apuzzo F, Ferrulli VE, et al. Dento-skeletal effects of mixed palatal expansion evaluated by postero-anterior cephalometric analysis. *Eur J Paediatr Dent.* 2014;15(1):59-62. [Full text link][PubMed][Google Scholar][Scopus]
25. Perillo L, De Rosa A, Iaselli F, et al. Comparison between rapid and mixed maxillary expansion through an assessment of dento-skeletal effects on posteroanterior cephalometry. *Prog Orthod.* 2014;15(1):46. doi: 10.1186/s40510-014-0046-9. [Full text link][CrossRef][PubMed][Google Scholar][Scopus]
26. Grassia V, d'Apuzzo F, DiStasio D, et al. Upper and lower arch changes after Mixed Palatal Expansion protocol. *Eur J Paediatr Dent.* 2014;15(4):375-380. [Full text link][PubMed][Google Scholar][Scopus] [WoS]
27. Grassia V, d'Apuzzo F, Jamilian A, et al. Comparison between rapid and mixed maxillary expansion through an assessment of arch changes on dental casts. *Prog Orthod.* 2015;16:20. doi: 10.1186/s40510-015-0089-6. [Full text link][CrossRef][PubMed][Google Scholar][Scopus] [WoS]
28. Lione R, Brunelli V, Franchi L, et al. Mandibular response after rapid maxillary expansion in class II growing patients: a pilot randomized controlled trial. *Prog Orthod.* 2017;18(1):36. doi: 10.1186/s40510-017-0189-6. [Full text link][CrossRef][PubMed][Google Scholar][Scopus] [WoS]
29. Ngan P. Biomechanics of maxillary expansion and protraction in Class III patients. *Am J Orthod Dentofacial Orthop.* 2002;121(6):582-583. doi: 10.1067/mod.2002.124168. [Full text link][CrossRef][PubMed][Google Scholar][Scopus] [WoS]
30. D'Apuzzo F, Grassia V, Quinzi V, et al. Paediatric Orthodontics. Part 4: SEC III protocol in Class III malocclusion. *Eur J Paediatr Dent.* 2019;20(4):330-334. doi: 10.23804/ejpd.2019.20.04.14. [Full text link][PubMed][Google Scholar][Scopus]
31. Generali C, Primozic J, Richmond S, et al. Three-dimensional evaluation of the maxillary arch and palate in unilateral cleft lip and palate subjects using digital dental casts. *Eur J Orthod.* 2017;39(6):641-645. doi: 10.1093/ejo/cjx019. [Full text link][CrossRef][PubMed][Google Scholar][Scopus] [WoS]
32. Smahel Z, Velemínská J, Trefný P, Müllerová Z. Three-dimensional morphology of the palate in patients with bilateral complete cleft lip and palate at the stage of permanent dentition. *Cleft Palate Craniofac J.* 2009;46(4):399-408. doi: 10.1597/07-199.1. [Full text link][CrossRef][PubMed][Google Scholar][Scopus]
33. Smahel Z, Trefný P, Formánek P, et al. Three-dimensional morphology of the palate in subjects with isolated cleft palate at the stage of permanent dentition. *Cleft Palate Craniofac J.* 2003;40(6):577-584. doi: 10.1597/1545-1569\_2003\_040\_0577\_tmotpi\_2.0.co\_2. [Full text link][CrossRef][PubMed][Google Scholar][Scopus]
34. De Luca Canto G, Pachêco-Pereira C, Lagravere MO, et al. Intra-arch dimensional measurement validity of laser-scanned digital dental models compared with the original plaster models: a systematic review. *Orthod Craniofac Res.* 2015;18(2):65-76. doi: 10.1111/ocr.12068. [Full text link][CrossRef][PubMed][Google Scholar][Scopus] [WoS]
35. Shahen S, Carrino G, Carrino R, et al. Palatal volume and area assessment on digital casts generated from cone-beam computed tomography scans. *Angle Orthod.* 2018;88(4):397-402. doi: 10.2319/091117-611.1. [Full text link][CrossRef][PubMed][Google Scholar][Scopus] [WoS]
36. Smahel Z, Trefný P, Formánek P, et al. Three-dimensional morphology of the palate in subjects with unilateral complete cleft lip and palate at the stage of permanent dentition. *Cleft Palate Craniofac J.* 2004;41(4):416-423. doi: 10.1597/03-053.1. [Full text link][CrossRef][PubMed][Google Scholar][Scopus]
37. Lewis BR, Stern MR, Willmot DR. Maxillary anterior tooth size and arch dimensions in unilateral cleft lip and palate. *Cleft Palate Craniofac J.* 2008;45(6):639-646. doi: 10.1597/07-078.1. [Full text link][CrossRef][PubMed][Google Scholar][Scopus]
38. Iwasaki T, Yanagisawa-Minami A, Suga H, et al. Rapid maxillary expansion effects of nasal airway in children with cleft lip and palate using computational fluid dynamics. *Orthod Craniofac Res.* 2019;22(3):201-207. doi: 10.1111/ocr.12311. [Full text link][CrossRef][PubMed][Google Scholar][Scopus]
39. Ayub PV, Janson G, Gribel BF, et al. Analysis of the maxillary dental arch after rapid maxillary expansion in patients with unilateral complete cleft lip and palate. *Am J Orthod Dentofacial Orthop.* 2016;149(5):705-715. doi: 10.1016/j.ajodo.2015.11.022. [Full text link][CrossRef][PubMed][Google Scholar][Scopus] [WoS]

### Fabrizia D'APUZZO

DDS, MS, PhD, Research Fellow  
 Multidisciplinary Department of Medical-Surgical and Dental Specialties  
 University of Campania Luigi Vanvitelli Naples  
 Naples, Italy



### CV

Fabrizia d'Apuzzo is a graduate of Dental Medicine (October 2012 with honors) from the Second University of Naples (Italy). She attended the "Université Lille II Droit et Santé" in Lille (France) between September 2010 and April 2011 as an "Erasmus" student, and the University of Trieste (Italy) on a 3-month travel grant from December 2011 to perform her experimental thesis. She was awarded her Postgraduate Diploma in Orthodontics in February 2017 and her PhD in Biomedical and Biotechnological Sciences in December 2019. And she is currently a Research Fellow at the University of Campania Luigi Vanvitelli, Naples (Italy).

Dr. d'Apuzzo has authored and co-authored more about 30 articles, 3 book chapters and over 40 posters. She has been a speaker at international conferences and she received several awards and distinctions.

## Questions

### 1. Cleft lip and palate is a?

- a. Congenital craniofacial birth anomaly;
- b. Congenital dental disorder;
- c. Nosocomial infection;
- d. Acquired disorder.

### 2. What is the etiology of cleft lip and palate?

- a. Environmental;
- b. Genetic;
- c. Epigenetic;
- d. All of the aforementioned.

### 3. What is the first surgery performed in CLP patients?

- a. Alveolar bone graft;
- b. Lip;
- c. Soft palate;
- d. Hard palate.

### 4. Patients with cleft lip and palate can have

- a. Skeletal maxillary constriction;
- b. Dental posterior crossbite;
- c. Reduced intercanine widths;
- d. All of the aforementioned.

**ICCMO**  
 The International College  
 of Cranio-Mandibular Orthopedics  
**INDIA SECTION**

+91 636 165 2207  
 www.iccmoindia.com

## 2ND ICCMO INDIA CONGRESS

### "THE AIRWAY TRUTH"

First ever Speciality Conference in India on Airway in  
 Dental Sleep Medicine

Come and enjoy Neuromuscular Dentistry. Broaden your horizon and enhance your practice to  
**PRECISION, MUSCLE-PHYSIOLOGY-MEASURED, GOLDEN-PROPORTIONAL-AESTHETIC DENTISTRY!**  
 Featuring renowned Speakers in the field from all over the world

Dr. Raj Ravi, Dr. Konstantin Ronkin, Dr. Darick Nordstrom, Ms. Julia Worrall, Dr. Stanislav Blum.jpg, Dr. Tatu Joy, Mr. Bryan Ferre, Dr. Tammara Heit,  
 Dr. Kelly Wells, Dr. Girish P.V., Ms. Esthah Yasmin, Dr. Uttam Agarwal, Dr. Sonia Malic, Dr. Shifa Arshad, Dr. Kalina Borska, Dr. Atul Sattar, Mr. Cole Clayton.