

CONE BEAM TOMOGRAPHY AND PANORAMIC RADIOGRAPHY IN LOCALIZATION OF IMPACTED MAXILLARY CANINE AND DETECTION OF ROOT RESORPTION

Seden Akan^{1a*}, Husamettin Oktay^{2b}

¹Department of Orthodontics, Faculty of Dentistry, Altınbaş University, Bakırköy / İstanbul, Turkey

²Department of Orthodontics, İstanbul Medipol University Faculty of Dentistry, İstanbul, Turkey

^aDDS, PhD, Assistant Professor; e-mail: sedenakandt@hotmail.com; ORCIDiD: <https://orcid.org/0000-0001-7955-3086>

^bDDS, PhD, Professor; e-mail: hoktay@medipol.edu.tr; ORCIDiD: <https://orcid.org/0000-0001-7862-2983>

ABSTRACT

[https://doi.org/10.25241/stomaeduj.2021.8\(2\).art.3](https://doi.org/10.25241/stomaeduj.2021.8(2).art.3)

Introduction The aim of this study was to evaluate cases of impacted maxillary canines (IMC) using cone beam tomography (CBCT) and panoramic images in an attempt to assess if panoramic radiographs can provide information compatible with CBCT results regarding canine position and root resorption.

Methodology Fifty-six impacted maxillary canines from 48 patients were radiographically evaluated. The positions of the canine teeth were classified by Sector localization on panoramic radiographs and the same teeth were also analyzed by KPG on CBCT. Root resorptions in maxillary lateral incisors were also evaluated on CBCT. The relationships between panoramic and CBCT findings were compared by Chi-square test and Fischer's exact test.

Results Statistically significant correlations were found between panoramic Sectors and KPG indexes ($p < 0.001$). KPG index values of 1, 3 and 4 corresponded to the panoramic Sectors 1, 4 and 5, respectively; but KPG index 2 matched the panoramic Sectors 3 and more often 2. Mid-alveolar impaction generally coincided with score 1 for both KPG index and panoramic Sector. In palatally IMC, this score value was generally 2 or 3 for the KPG index and 4 for the panoramic Sector ($p \leq 0.001$). Root resorptions in maxillary lateral incisors showed significant differences according to Sector localization and KPG index ($p < 0.05$), namely they coincided with 2 and 3 in Sector evaluation and 2, 3 and 4 in KPG index.

Conclusions Sector location on OPG is found to be related to KPG index on CBCT, and it can help evaluate mainly certain positions of impacted canines; thus, unnecessary CBCT scans are not requested.

KEYWORDS

Impacted Canine; KPG Index; Radiography Dental; Digital Radiography Panoramic; Sector Classification.

1. INTRODUCTION

Maxillary canines play important roles in facial esthetics, dental arch development, and oral cavity functions. Non-erupted maxillary canines are relatively common because these teeth develop deep within the maxilla and follow a longer path to erupt into the oral cavity when compared to other teeth [1]. An impacted tooth can be defined as the tooth that has failed to erupt into the proper position in the dental arch within the normal period of growth, and maxillary canines are the most common teeth suffering from impaction except third molars. The prevalence of their impaction ranges from 1% to 3% in the general population [2-4].

The determination of impacted canine positions is critical for the planning of orthodontic-surgical treatment. The panoramic radiographic evaluation is the most common clinical approach used by orthodontists for this procedure. It should be known, however, that panoramic radiographs have some limitations in evaluating the labiopalatal positions of impacted canines [5]. In addition, it is difficult to localize and determine the root resorptions of adjacent teeth with this radiographic method because of the superimposition of the related structures, leading to a difficulty in distinguishing many significant details [6].

Many studies have been carried out to overcome these shortcomings regarding panoramic radiographic

 **OPEN ACCESS** This is an Open Access article under the CC BY-NC 4.0 license.
Peer-Reviewed Article

Citation: Akan S, Oktay H. Cone beam tomography and panoramic radiography in localization of impacted maxillary canine and detection of root resorption. *Stoma Edu J.* 2021;8(2):106-112.

Received: December 18, 2020; **Revised:** January 10, 2021; **Accepted:** January 21, 2021; **Published:** January 25, 2021

***Corresponding author:** Dr. Seden Akan; Altınbaş Üniversitesi Diş Hekimliği Fakültesi Zuhuratbaba Mahallesi, İncirli Caddesi, No:11-A 34147 Bakırköy, İstanbul, Turkey.

Tel/Fax: 0090535 5113760; e-mail: sedenakandt@hotmail.com

Copyright: © 2021 the Editorial Council for the Stomatology Edu Journal.

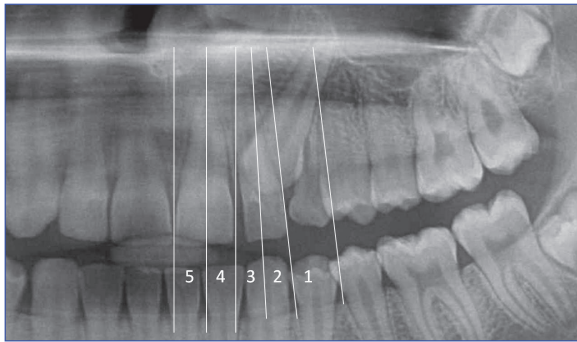


Figure 1. Modified Sector classification according to the mesiodistal position of the canine cusp tip on OPG.

evaluations [7-11]. One of them belonged to Ericson and Kurol [8] who proposed some measurements on panoramic radiographs to predict the possible impaction of maxillary canines in relation to the adjacent lateral incisors.

Their sector classification was then modified by Leonardi et al [12] and Bacetti et al [13] and gained popularity among the orthodontists and dental radiologists [14,15].

Cone-beam computed tomography (CBCT) used for three-dimensional visualization has gained more popularity in dental clinics during the last 3 decades [16] and at present, it has been accepted as the most accurate method in impacted tooth localization [17] although CBCT gives more radiation to the patients than conventional radiographs. In order to develop evidence-based guidelines on the use of CBCT in dental and maxillofacial imaging, a project named SEDENTEXCT was accomplished between 2008-2011 in Europe [17]. According to this project, CBCT records may be indicated only in cases where inadequate information is obtained from conventional radiographs about impacted canines and their localizations.

CBCT presents a reliable guidance of the used mechanics, force, and treatment style to move the impacted canines efficiently with lower complications. To standardize the classification of impacted maxillary canines and to predict treatment difficulty, KPG index was introduced by Kau et al [18] in 2009. The aims of the present study were to investigate if the panoramic radiographs can provide information related with CBCT results regarding canine position and root resorption.

2. SUBJECTS AND METHODS

This retrospective radiographic study, being approved by the institutional ethical board (108400987-97-86), was carried out on the diagnostic records of 48 patients applied at the Orthodontic Department of the Dental School at Istanbul Medipol University; the patients complained of maxillary canine impaction. The age of the subjects ranged between 12-34 and the mean age was 18.31 ± 4.99 years. The patients having any syndrome, tooth aplasia, or undeveloped canine root were excluded. Bilateral canine impaction

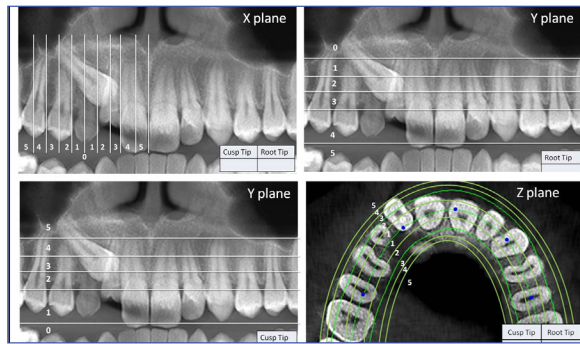


Figure 2. KPG index is calculated by summing the scores (0 to 5 scores) of the canine cusp tip and root tip on x, y and z planes.

was seen in 8 patients, while 40 of them had unilateral impaction. After a routine panoramic radiographic evaluation, CBCT scans were needed in order to obtain more detailed information on the impacted canines for button operation. Panoramic records (OPG) were obtained by Carestream (Kodak) OPG Dental Machine (Carestream, Canada). CBCT scans were taken by I-CAT Next Generation & i-Cat VisionQ machine, (Imaging Sciences International, LLC, Hatfield, PA) at a setting of 120 kVp and 3.7 m.

Both the OPG records and CBCT images of the 56 impacted canines were analyzed. The mesiodistal positions of the canine crowns were determined on panoramic radiographs and classified by the Sector classification method, which was modified by Leonardi et al [12] and Bacetti et al [13] (Fig. 1). The KPG index, a novel index based on 3D CBCT images, was calculated by summing the scores (0 to 5 scores) of the canine cusp tip and root tip on x, y and z planes (Fig. 2). The total KPG scores between 0 and 9 were classified as follows: 10 as easy, 14 as moderate, 15 and 19 as difficult and 20 and above as extremely difficult. These categories were named as 1, 2, 3, and 4 beginning from the easy group in order to make the comparison with the Sector groups easy. The root resorptions of adjacent maxillary lateral incisors and labiopalatal positions of the impacted canines were also evaluated on CBCT. The labiopalatal positions of the impacted canines were classified as labial, mid-alveolar, and palatal. Root resorptions were settled as yes or no. The labiopalatal positions of the impacted canines and resorptions at lateral incisors were correlated with the KPG indexes and Sector classifications. Panoramic and CBCT images were scored twice by one author (S.A.) at a two-week interval. Intraobserver reliability was assessed by Kappa coefficient.

The relationships between panoramic and CBCT findings were investigated by Chi-square and Fisher's exact tests. The data analysis was performed using SPSS 16.0 software package (SPSS Inc., Chicago, IL, USA). P values lower than 0.05 were accepted as statistically significant.

Table 1. Relationships between Sector classification and KPG index.

KPG Index	Sector Classification					
	1	2	3	4	5	Total
1	11	0	0	2	0	13
2	1	10	9	5	0	25
3	1	1	5	8	1	16
4	0	0	0	0	2	2
Total	13	11	14	15	3	56

p<0.001

Table 2. Relationships among KPG index, Sector classification and CBCT findings.

		KPG Index					Sector Classification					
		1	2	3	4	Total	1	2	3	4	5	Total
Lateral incisor contact	No contact	12	6	6	2	26	12	2	2	8	2	26
	Contact	1	19	10	0	30	1	9	12	7	1	30
Lateral incisor root resorption	No resorption	13	11	8	2	34	13	4	6	9	2	34
	Resorption	0	14	8	0	22	0	7	8	6	1	22
Labiopalatal position	Bukkal	2	3	5	0	10	3	0	6	1	0	10
	Mid-alveolar	9	4	0	0	13	9	4	0	0	0	13
	Palatal	2	18	11	2	33	1	7	8	14	3	33

Root resorption of the maxillary lateral incisors was found more in score 2 of the KPG index (p=0.004) and in score 3 of the Sector classification (p=0.011). The indicative scores were 2 or 3 in KPG index and; 2, 3 and 4 in panoramic Sectors for palatally impacted canines (p≤0.001).

3. RESULTS

Kappa coefficients showing intraobserver reliability were high for both panoramic and CBCT images: 0.748 for lateral incisor root resorption and 0.858 for labiopalatal position of the impacted canine. Table I shows a statistically significant association between Sector classification and KPG index (p<0.001). KPG indexes 1, 3, and 4 corresponded to panoramic Sectors 1, 4, and 5, respectively, while KPG index 2 related to panoramic Sectors 2 and 3. The results regarding the labiopalatal positions of the impacted canines and resorptions at the lateral incisors are shown in Table II. As can be seen from these tables, mid-alveolar impaction generally coincided with score 1 in both KPG and Sector evaluations. The indicative scores were 2 or 3 in the KPG index and; 2, 3 and 4 in panoramic Sectors for palatally impacted canines (p≤0.001). In labially impacted canines, the indicative score was 3 for both KPG index and the panoramic sector. The root resorption of maxillary lateral incisors showed significant differences according to Sector localization and KPG index (p<0.05). Resorption was found more in scores 2 and 3 in both KPG and Sector evaluations.

4. DISCUSSION

The determination of impacted maxillary canine positions is very important to prevent root resorp-

tions in adjacent teeth, to schedule ortho-surgical procedures, and to give an opinion about orthodontic treatment time. It has been stated that one of the major reasons for treatment failure of impacted canines is mistaken location and directional of traction (40.5%) [19]. The main objectives of the present study were to assess the relation between 2D and 3D visualization of impacted maxillary canines, to estimate labiopalatal positions of impacted canines from panoramic radiographs, which were routinely used in orthodontic clinics, and to evaluate root resorptions in lateral incisors by CBCT. CBCT is the best contemporary method to diagnose and localize the impacted canines and their possible complications [6,20,21]. It has excellent image quality and high diagnostic accuracy for many tasks, such as the detection of bone defects, implant treatment planning, impacted third molar and canine teeth, and root resorption evaluation.

In the present study, KPG index values obtained according to CBCT were gathered in more localized categories than Sector classification made according to Panoramic radiograph. For example, while lateral tooth contact and root resorption appear only at 2 and 3 in the KPG index, they are evaluated in almost all classes in the Sector classification. This result may suggest once again that the diagnostic capability of the CBCT may be clearer.

According to the radiation dose which is the main disadvantage of the CBCT, although the CBCT exposure dose is relatively low compared with that of conventional CT, it is up to 10 times higher than that of intraoral and extraoral radiography used in dentistry [22,23]. To give a more practical example, it has been revealed that the average effective radiation dose of panoramic radiography is relatively lower, ranging from 4.1 to 36 μSv (2-3 days of natural background radiation level), whereas that of CBCT ranges from 19 to 368 μSv (11 days of natural background radiation level) [24, 25]. Thus, a reason for an examination and optimization of this radiographic technique are strongly needed [26]. It is accepted that CBCT scans should only be requested when there is a potential for CBCT images to provide new information not provided by conventional radiograph [17]. The cases in which diagnosis of impacted teeth is made in initial conventional orthodontic records, CBCT might be requested as a compliment [17]. Should that be the case, CBCT scan protocols should include a partial field of view comprising the maxilla or the mandible, only. In the light of this information, the present study attends to define a correlation between 2D and 3D qualitative analyses, at least when unnecessary CBCT scans are not requested.

The KPG index, introduced in 2009, presents an opportunity to localize the impacted canines using CBCT. Kau et al [27] carried out a study in 2013 to determine the level of agreement of orthodontists in the management of impacted maxillary canines, and found that the KPG index showed a good level of agreement with the clinician's perception of difficulty. Dalessandri et al [28] investigated the agreement between OPG based 2D measurements and the KPG index on 105 impacted maxillary canines. These authors stated that KPG index had higher intra- and interrater agreement than those of the 2D index, and that the KPG index allows clinicians to exactly evaluate the position of impacted canines [28]. As for panoramic radiograph, OPG has been accepted as a standard record in orthodontics. In addition to the clinical examination of the palatal lump, radiographic evaluation is generally needed to identify the positions of impacted canines. With a low radiation dose, OPG provides an overview of all dentoskeletal structures, but several factors, such as superimposition of the structures and inadequate visualization of anterior maxilla in horizontal and vertical planes, affect the image quality of the panoramic radiograph. Sector classification, carried out on OPG, is a very important diagnostic tool used in the evaluation of impacted canines [10,13,29]. Jung et al [15] showed that labially impacted canines were frequently in Panoramic Sectors 1, 2, and 3, mid-alveolus impacted canines in Sector 4, and palatally impacted canines in Sector 5. According to these authors, the labiopalatal positions of impacted canines can be predicted by

Sector location on OPG. Olive [29] stated that there was a significant relationship between the mesiodistal position of impacted canines and the treatment time. Canines impacted in Sector 4 emerged after 21 months of treatment and canines in Sectors 2 and 3 emerged after 8 months of treatment.

In literature, there are studies [21,28,30-34] comparing the localization of impacted canine by means of 2D and 3D indexes. Sosars et al [30] evaluated 106 palatally displaced maxillary canines and they concluded that panoramic measurements were not reliable predictors of resorptions, except for severe resorptions, of the neighbor teeth. Khan Mohammed et al [31] stated that CBCT showed an increased accuracy of 31% compared to Panoramic radiography in localizing impacted maxillary canines. Haney et al [32] compared the differences between 2 imaging modalities regarding diagnosis and treatment planning of impacted maxillary canines. Two and three dimensional images of 25 impacted canines were evaluated by 7 of their faculty members, and significant disagreement was observed among the evaluators. As a result, they concluded that three-dimensional volumetric imaging might provide more accurate information for diagnosis and treatment plans. In a similar study carried out by Algerban et al [21], OPG and CBCT images were obtained from 60 consecutive patients who had impacted or ectopically erupting maxillary canines, and these images were analyzed by 11 examiners. The results of that study showed that CBCT was more sensitive than conventional radiography for both canine localization and identification of root resorption of adjacent teeth. Although recent studies have shown that CBCT is the most sensitive and reliable technique in the evaluation of craniofacial structures, as stated previously, it gives higher radiation doses to the patients than the conventional radiographs, thus it has not come into use routinely in orthodontic clinics [33]. For this reason, it was necessary to detect possible relationships between Sector classification on OPG and 3D KPG index. If a strong relationship is detected between them, OPG can be used safely in impacted canine cases. The results of the present study showed that KPG indexes 1, 3, and 4 mostly matched panoramic Sectors 1, 4, and 5, respectively, and that KPG index 2 matched Sector 2 and 3. According to these results, it could be said that the Sector analysis is largely compatible with the KPG index.

The accurate diagnosis of exact canine position, potential contacts, and root resorptions of the adjacent teeth may reduce complications during treatment. Jung et al [15] found root resorption in the adjacent teeth only in Sectors 3, 4, and 5. Ericson and Kurol [8] stated that canines in the Sectors 3, 4, and 5 comprised 65% of the related root resorptions.

In the present study, all of the root resorptions were in Sectors 2, 3, and 4 and in KPG index 2 and 3. There was no resorption case in Sector 5. As can be seen from Table 1, only 3 teeth of 56 impacted canine teeth were in sector 5, and 2 of them matched KPG index 4. This means that the canines in Sector 5 have a deep localization. But it should not be passed on without being told; these are a rather small numbers for drawing reliable conclusions about these scores. This fact may explain the difference between the results of the present study and those of Jung et al [15] and Ericson and Kuroi [8]. These results showed that the Sector classification of the impacted canines may help to detect root resorptions at the adjacent teeth. If Sector evaluation on OPG is 2 or above, root resorption may have been at the adjacent lateral incisors, and thus CBCT evaluation should be recommended for detailed examination. The determination of the labiopalatal positions of the canine cusp tips was an important issue in the diagnosis and treatment planning of impacted canine cases. This evaluation can be made by Sector classification on OPG or KPG index on CBCT [10,15]. Jung et al [15] evaluated 73 impacted maxillary canines of 63 patients by OPG and CBCT, and classified them by sector location. According to their results, 26 out of the 30 labially impacted canines were located in Sectors 1, 2, and 3, while 15 out of the 23 mid-alveolus impacted canines and 17 out of the 20 palatally impacted canines were in Sectors 4 and 5. In the present study, roughly half of the labially impacted canines had 3 KPG and Sector scores. All mid-alveolar impacted canines had scores 1 and 2 in both KPG index and Sector classification. Of the 33 palatally impacted canines, 29 teeth were in the KPG index 2 and 3 and in Sectors 2, 3, and 4. These results suggest that sector location on OPG could help to predict the labiopalatal positions of the impacted canines as it is done by KPG index on CBCT.

5. CONCLUSIONS

The results of the present study can be summarized as follows:

REFERENCES

1. da Silva Santos LM, Bastos LC, Oliveira-Santos C, et al. Cone-beam computed tomography findings of impacted upper canines. *Imaging Sci Dent.* 2014;44 (4):287-292. <https://doi.org/10.5624/isd.2014.44.4.287>
[PubMed](#) [Google Scholar](#)
2. Thilander B, Jakobsson SO. Local factors in impaction of maxillary canines. *Acta Odontol. Scand.* 1968;26(2):145-168. <https://doi.org/10.3109/00016356809004587>
[PubMed](#) [Full Text](#) [Google Scholar](#) [Scopus](#)
3. Walker L, Enciso R, Mah J. Three-dimensional localization of maxillary canines with cone-beam computed tomography. *Am J Orthod Dentofacial Orthop.* 2005;128 (4):418-423. [https://doi.org/10.1016/s0084-3717\(08\)70464-1](https://doi.org/10.1016/s0084-3717(08)70464-1)
[PubMed](#) [Full Text](#) [Cross Ref](#) [Google Scholar](#) [Scopus](#) [WoS](#)
4. Rossini G, Cavallini C, Cassetta M, et al. Localization of impacted maxillary canines using cone beam computed tomography. Review of the literature. *Ann. Stomatol. (Roma).* 2012;3 (1):14-18. <https://doi.org/10.1016/j.tripleo.2007.01.030>
[PubMed](#) [Full Text Links](#) [Google Scholar](#) [WoS](#)
5. Freisfeld M, Dahl IA, Jager A, et al. X-ray diagnosis of impacted upper canines in panoramic radiographs and computed

- KPG indexes 1, 3, and 4 corresponded to panoramic Sectors 1, 4, and 5, respectively, while KPG index 2 is related to panoramic Sectors 2 and 3,
- Lateral incisor root resorption was seen predominantly in KPG index 2 and 3, and in Sectors 2, 3, and 4.
- Score 1 and 2 for both KPG index and Sector classification showed mid-alveolar impaction; score 3 showed labial impaction for both evaluation groups; and score 2 and 3 in KPG index and 2, 3, and 4 in Sector classification were related to palatally impacted canines.
- OPG could help the evaluation of impacted maxillary canine cases by providing information related to CBCT results.

CONFLICT OF INTEREST

The authors declare no conflict of interest.

ACKNOWLEDGMENTS

None

FUNDING

The authors declare that they have not received any funding.

COMPETING INTERESTS

The authors declare that they have no competing interests and revised the article critically. All authors read and approved the final manuscript.

ETHICS APPROVAL AND CONSENT TO PARTICIPATE

Written informed consent containing all the information about records and usage for study was obtained from all patients. All procedures in this study were approved by the Ethical Board of the Istanbul Medipol University (108400987-97-86) and complied with the Code of Ethics of the World Medical Association (Declaration of Helsinki).

AUTHOR CONTRIBUTIONS

SA: contributed to the concept and design of the study, to the acquisition, analysis and interpretation of the data and drafting the article. HO: participated by critically revising the article. All authors read and approved the final manuscript.

tomographs. *J Orofac Orthop.* 1999;60 (3):177-184. <https://doi.org/10.1007/bf01365264>

- [PubMed](#) [Full Text Links](#) [Cross Ref](#) [Google Scholar](#) [Scopus](#)
6. Almuhtaseb E, Mao J, Mahony D, et al. Three-dimensional localization of impacted canines and root resorption assessment using cone beam computed tomography. *J Huazhong Univ Sci Technol Med Sci.* 2014;34 (3):425-430. <https://doi.org/10.1007/s11596-014-1295-z>
[PubMed](#) [Full Text Links](#) [CrossRef](#) [Google Scholar](#) [Scopus](#) [WoS](#)
 7. Stewart JA, Heo G, Glover KE, Williamson PC, Lam EW, Major PW. Factors that relate to treatment duration for patients with palatally impacted maxillary canines. *Am J Orthod Dentofacial Orthop.* 2001;119 (3):216-225. <https://doi.org/10.1067/mod.2001.110989>
[PubMed](#) [Full Text Links](#) [CrossRef](#) [Google Scholar](#) [Scopus](#) [WoS](#)
 8. Ericson S, Kuroi J. Early treatment of palatally erupting maxillary canines by extraction of the primary canines. *Eur J Orthod.* 1988;10 (4):283-295. <https://doi.org/10.1093/ejo/10.4.283>
[PubMed](#) [Full Text Links](#) [CrossRef](#) [Google Scholar](#) [Scopus](#) [WoS](#)

9. Crescini A, Nieri M, Buti J, et al. Orthodontic and periodontal outcomes of treated impacted maxillary canines. *Angle Orthod.* 2007;77(4):571-577. <https://doi.org/10.2319/080406-318.1>
[PubMed](#) [CrossRef](#) [Google Scholar](#) [WoS](#)
10. Lindauer SJ, Rubenstein LK, Hang WM, et al. Canine impaction identified early with panoramic radiographs. *J Am Dent Assoc.* 1992;123(3):91-92, 95-97.
<https://doi.org/10.14219/jada.archive.1992.0069>
[PubMed](#) [Full Text Links](#) [CrossRef](#) [Google Scholar](#) [Scopus](#) [WoS](#)
11. Warford JH, Jr., Grandhi RK, Tira DE. Prediction of maxillary canine impaction using sectors and angular measurement. *Am J Orthod Dentofacial Orthop.* 2003;124(6):651-655.[https://doi.org/10.1016/s0889-5406\(03\)00621-8](https://doi.org/10.1016/s0889-5406(03)00621-8)
[PubMed](#) [Full Text Links](#) [CrossRef](#) [Google Scholar](#) [Scopus](#) [WoS](#)
12. Leonardi M, Armi P, Franchi L, Baccetti T. Two interceptive approaches to palatally displaced canines: a prospective longitudinal study. *Angle Orthod.* 2004;74(5):581-586. [https://doi.org/10.1043/0003-3219\(2004\)074<0581:TIATPD>2.0.CO;2](https://doi.org/10.1043/0003-3219(2004)074<0581:TIATPD>2.0.CO;2).
[PubMed](#) [Google Scholar](#) [Scopus](#) [WoS](#)
13. Baccetti T, Leonardi M, Armi P. A randomized clinical study of two interceptive approaches to palatally displaced canines. *J Orthod.* 2008;30(4):381-385. <https://doi.org/10.1093/ejo/cjn023>
[PubMed](#) [Full Text Links](#) [CrossRef](#) [Google Scholar](#) [Scopus](#) [WoS](#)
14. Alessandri Bonetti G, Zanarini M, Danesi M, et al. Percentiles relative to maxillary permanent canine inclination by age: a radiologic study. *Am J Orthod Dentofacial Orthop.* 2009;136(4):486 e481-486; discussion 486-487.<https://doi.org/10.1016/j.ajodo.2009.01.022>
[PubMed](#) [Full Text Links](#) [CrossRef](#) [Google Scholar](#) [Scopus](#) [WoS](#)
15. Jung YH, Liang H, Benson BW, et al. The assessment of impacted maxillary canine position with panoramic radiography and cone beam CT. *Dentomaxillo fac Radiol.* 2012;41(5):356-360. <https://doi.org/10.1259/dmfr/14055036>
[PubMed](#) [Full Text Links](#) [CrossRef](#) [Google Scholar](#) [Scopus](#) [WoS](#)
16. Mah JK, Danforth RA, Bumann A, Hatcher D. Radiation absorbed in maxillofacial imaging with a new dental computed tomography device. *Oral Surg Oral Med Oral Pathol Oral Radiol Endod.* 2003;96(4):508-513. [https://doi.org/10.1016/s1079-2104\(03\)00350-0](https://doi.org/10.1016/s1079-2104(03)00350-0)
[PubMed](#) [Full Text Links](#) [CrossRef](#) [Google Scholar](#) [Scopus](#) [WoS](#)
17. The SEDENTEXCT Project. *Radiation Protection: Cone Beam CT for Dental and Maxillofacial Radiology.* Evidence Based Guidelines. Luxembourg: European Commission; 2011:1-139.
18. Kau CH, Pan P, Gallerano RL, English JD. A novel 3D classification system for canine impactions--the KPG index. *Int J Med Robot.* 2009;5(3):291-296. <https://doi.org/10.1002/rcs.260>
[PubMed](#) [CrossRef](#) [Google Scholar](#) [Scopus](#) [WoS](#)
19. Becker A, Chaushu G, Chaushu S. Analysis of failure in the treatment of impacted maxillary canines. *Am J Orthod Dentofacial Orthop.* 2010;137(6):743-754. <https://doi.org/10.1016/j.ajodo.2008.07.022>
[PubMed](#) [Full Text Links](#) [CrossRef](#) [Google Scholar](#) [Scopus](#) [WoS](#)
20. Botticelli S, Verna C, Cattaneo PM, et al. Two- versus three-dimensional imaging in subjects with unerupted maxillary canines. *Eur J Orthod.* 2011;33(4):344-349. <https://doi.org/10.1093/ejo/cjq102>
[PubMed](#) [Full Text Links](#) [CrossRef](#) [Google Scholar](#) [Scopus](#) [WoS](#)
21. Alqerban A, Jacobs R, Fieuws S, Willems G. Comparison of two cone beam computed tomographic systems versus panoramic imaging for localization of impacted maxillary canines and detection of root resorption. *Eur J Orthod.* 2011;33(1):93-102. <https://doi.org/10.1093/ejo/cjq034>
[PubMed](#) [Full Text Links](#) [CrossRef](#) [Google Scholar](#) [Scopus](#) [WoS](#)
22. Roberts JA, Drage NA, Davies J, Thomas DW. Effective dose from beam CT examinations in dentistry. *Br J Radiol.* 2009;82(973):35-40. <https://doi.org/10.1259/bjr/31419627>
[PubMed](#) [Full Text Links](#) [CrossRef](#) [Google Scholar](#) [Scopus](#) [WoS](#)
23. Shin HS, Nam KC, Park H, et al. Effective doses from panoramic radiography and CBCT (cone beam CT) using dose area product (DAP) in dentistry. *Dentomaxillofac Radiol.* 2014;43(5):20130439. <https://doi.org/10.1259/dmfr.20130439>
[PubMed](#) [Full Text Links](#) [CrossRef](#) [Google Scholar](#) [WoS](#)
24. Kadesjö N, Lynds R, Nilsson M, Shi XQ. Radiation dose from X-ray examinations of impacted canines: cone beam CT vs two-dimensional imaging. *Dentomaxillofac Radiol.* 2018;47:20170305. <https://doi.org/10.1259/dmfr.20170305>
[PubMed](#) [Full Text Links](#) [Google Scholar](#)
25. Lee CYS, Koval TM, Suzuki JB. Low-dose radiation risks of computerized tomography and cone beam computerized tomography: Reducing the Fear and Controversy. *J Oral Implantol.* 2015; 41(5): e223–e230. <https://doi.org/10.1563/AAID-JOI-D-13-00221>
[PubMed](#) [Full Text Links](#) [CrossRef](#) [Google Scholar](#) [Wos](#)
26. Sonawane AU, Sunil Kumar JV, Singh M, Pradhan AS. Suggested diagnostic reference levels for paediatric X-ray examinations in India. *Radiat Prot Dosimetry.* 2011;147(3):423-428. <https://doi.org/10.1093/rpd/ncq458>
[PubMed](#) [Full Text Links](#) [CrossRef](#) [Google Scholar](#) [Scopus](#) [WoS](#)
27. Kau CH, Lee JJ, Souccar NM. The validation of a novel index assessing canine impactions. *Eur J Dent.* 2013;7(4):399-404. <https://doi.org/10.4103/1305-7456.120648>
[PubMed](#) [Full Text Links](#) [CrossRef](#) [Google Scholar](#) [Scopus](#)
28. Dalessandri D, Migliorati M, Visconti L, et al. KPG index versus OPG measurements: a comparison between 3D and 2D methods in predicting treatment duration and difficulty level for patients with impacted maxillary canines. *Biomed Res Int.* 2014;2014:537620.<https://doi.org/10.1155/2014/537620>
[PubMed](#) [Full Text Links](#) [CrossRef](#) [Google Scholar](#) [Scopus](#) [WoS](#)
29. Olive RJ. Factors influencing the non-surgical eruption of palatally impacted canines. *Aust Orthod J.* 2005;21(2):95-101. [PubMed](#) [Google Scholar](#) [Scopus](#)
30. Sosars P, Jakobsone G, Neimane L, Mukans M. Comparative analysis of panoramic radiography and cone-beam computed tomography in treatment planning of palatally displaced canines. *Am J Orthod Dentofacial Orthop.* 2020;157(5):719-727. doi: 10.1016/j.ajodo.2019.12.012.
[PubMed](#) [Full Text Links](#) [Google Scholar](#)
31. Mohammed AK, Sravani G, Vallappareddy D, et al. Localization of impacted canines - a comparative study of computed tomography and orthopantomography. *J Med Life.* 2020;13(1):56-63. doi: 10.25122/jml-2020-0001.
[PubMed](#) [Full Text Links](#) [Google Scholar](#)
32. Wriedt S, Jaklin J, Al-Nawas B, Wehrbein H. Impacted upper canines: examination and treatment proposal based on 3D versus 2D diagnosis. *J Orofac Orthop.* 2012;73(1):28-40. <https://doi.org/10.1007/s00056-011-0058-8>
[PubMed](#) [Full Text Links](#) [CrossRef](#) [Google Scholar](#) [Scopus](#)
33. Pittayapat P, Willems G, Alqerban A, et al. Agreement between cone beam computed tomography images and panoramic radiographs for initial orthodontic evaluation. *Oral Surg Oral Med Oral Pathol Oral Radiol.* 2014;117(1):111-119.<https://doi.org/10.1016/j.oooo.2013.10.016>
[PubMed](#) [Full Text Links](#) [CrossRef](#) [Google Scholar](#)
34. Haney E, Gansky SA, et al. Comparative analysis of traditional radiographs and cone-beam computed tomography volumetric images in the diagnosis and treatment planning of maxillary impacted canines. *Am J Orthod Dentofacial Orthop.* 2010;137(5):590-597.<https://doi.org/10.1016/j.ajodo.2008.06.035>
[PubMed](#) [Full Text Links](#) [CrossRef](#) [Google Scholar](#) [Scopus](#) [WoS](#)
35. Serrant PS, McIntyre GT, Thomson DJ. Localization of ectopic maxillary canines -- is CBCT more accurate than conventional horizontal or vertical parallax? *J Orthod.* 2014;41(1):13-18.<https://doi.org/10.1179/1465313313y.00000000076>
[PubMed](#) [CrossRef](#) [Google Scholar](#)

Seden AKAN

Department of Orthodontics
Faculty of Dentistry
Altınbaş University
Bakırköy / İstanbul, Turkey



CV

Seden Akan graduated from the Hacettepe University, Faculty of Dentistry, Ankara, Turkey in 2003. She enrolled on her PhD degree in 2004 and she was awarded her PhD degree by the Hacettepe University in 2010. Since 2018, she has been working as an assistant professor at the Department of Orthodontics within the Faculty of Dentistry of the Altınbaş University.

Questions

1. Which is the most common clinical approach used by orthodontists to determine the impacted canine position?

- a. Panoramic radiography;
- b. CBCT;
- c. Periapical radiography;
- d. Bite wing radiography.

2. According to the SEDENTEXT Project, in which cases it is indicated to have a CBCT records?

- a. In every impacted canine patient;
- b. In case inadequate information is obtained from conventional radiographs about impacted canines;
- c. Only adult patients with impacted canine;
- d. Answers a-d are correct.

3. The aim of the present study to evaluate?

- a. The efficiency of the CBCT to determine the impacted canine position;
- b. The efficiency of the Panoramic radiographs to determine the impacted canine position;
- c. The capacity of the impacted canine to resorb the root of the lateral tooth;
- d. The correlation between effectiveness of KPG index and sector classification.

4. According to the present study results, in which common regions was the lateral tooth root resorption found in the KPG and Sector analysis?

- a. 1;
- b. 2 and 3;
- c. 4;
- d. 1 and 2.